

Orientation of Cone-Beam Computed Tomography Image: Pursuit of Perfect Orientation Plane in Three Dimensions—A Retrospective Cross-Sectional Study

Rajiv Balachandran¹ Om Prakash Kharbanda¹ Karthik Sennimalai¹ Bala Chakravarthy Neelapu^{2,3}

¹Division of Orthodontics and Dentofacial Deformities, All India Institute of Medical Sciences, New Delhi, India

²Department of Computational Instrumentation, Central Scientific Instruments Organisation, Chandigarh, India

³Department of ECE, Koneru Lakshmaiah Education Foundation, Andhra Pradesh, India

Address for correspondence Om Prakash Kharbanda, BDS, MDS, MOrth RCS, MMed, FDS, RCS, Division of Orthodontics and Dentofacial Deformities, Centre for Dental Education and Research, All India Institute of Medical Sciences, New Delhi 110029, India (e-mail: opk15@hotmail.com).

Ann Natl Acad Med Sci (India) 2019;55:202–209

Abstract

Objective This study aimed to evaluate the reproducibility of nine reference planes used in orientation of as-received cone-beam computed tomography (CBCT) images in all three dimensions.

Materials and Methods The study was conducted on CBCT images of 15 adult subjects (mean age 21.2 ± 5.8 years). The anonymized CBCT images were oriented using five different methods created from nine reference planes by two experienced orthodontists. For each subject, pitch, yaw, and roll changes with five orientation methods were recorded twice by each observer.

Statistical Analysis The inter- and intraobserver agreement was tested using intra-class correlation (ICC) and Bland–Altman plot. The intra- and interobserver error was analyzed using paired *t*-test. Analysis of variance and paired *t*-test were used to analyze the differences among the various pitch, roll, and yaw orientation planes.

Results Inter- and intraobserver agreement (ICC, 0.9) was excellent for all the nine reference planes. The interobserver reliability showed statistically significant differences for four planes namely Frankfort horizontal plane constructed on right side ($p = 0.014$) and left side ($p = 0.000$), transorbital plane ($p = 0.001$), and midsagittal plane on top view ($p = 0.036$); however, the mean differences were clinically insignificant.

Conclusion The landmark-based nine reference planes used in this study to orient CBCT images showed good reproducibility. Therefore, these reference planes can be used to orient CBCT images and can be incorporated into automated software.

Keywords

- ▶ cone-beam computed tomography
- ▶ orthodontics
- ▶ orthognathic surgery
- ▶ cephalometry
- ▶ standardization

Introduction

Standardization of head orientation is crucial in treatment planning and evaluation of treatment effects in patients with skeletal deformities. Natural head position (NHP) is recommended for two-dimensional (2D) and three-dimensional (3D) imaging/photography.^{1–3} NHP is the natural position of the head in which subject rest their head habitually. It is most reproducible position for clinical photographs and

cephalograms acquisition, which are important modalities in quantifying the dentofacial deformities in traditional orthodontic/orthognathic surgical planning.⁴ NHP also represents the true aesthetic and functional anatomic form of the face.⁵

Three-dimensional cone-beam computed tomography (CBCT) is considered to be a modern state of the art imaging. It allows a smooth digital workflow from diagnosis to treatment planning and execution by integration with other digital technologies like digital models and 3D

stereophotogrammetry. The virtual 3D models generated from CBCT images have been used for treatment planning and to assess the treatment and growth changes.⁶⁻⁹ In recent years, various 3D software programs have been introduced for the analysis of CBCT data^{10,11} and 3D cephalometric analysis.¹²⁻¹⁴

During CBCT acquisition, the patient's head is stabilized throughout the scanning procedure by various methods, such as the chin rest and head-positioning devices, which hold the patient's head in a stable but random orientation. Treatment planning and assessment made using a randomly orientated head is difficult and potentially inaccurate. Ruelas et al showed that the orientation of CBCT image strongly influences the quantification of growth changes assessed using serial CBCTs.¹⁵

Inconsistencies in the orientation plane among the samples may lead to inconsistent measurements. For example, in case of clockwise rotation of the head, the mandible would appear to be backwardly placed which is otherwise normal. Similarly, the definition of boundaries of different pharyngeal airway space can be influenced by the inaccuracies in orientation of CBCT image.¹⁶

Various authors suggested different methods for orienting the patient head during CBCT acquisition that includes (1) stereophotogrammetry, (2) facial markings along laser lines, (3) clinical photographs and the Pose from Orthography and Scaling with Iterations (POSIT) algorithm, (4) digital orientation sensing, (5) handheld 3D camera measuring system, and (6) laser scanning.^{1,2,17-19} However, these methods are impractical in routine clinical practice.

On the other hand, reorienting the CBCT images using stable cranial landmarks and reference structures may be a practical alternative.²⁰ In literature, different orientation methods have been reported for the orientation of CBCT images. Most of these methods utilize the modification of common 2D planes such as Frankfort horizontal (FH) plane and focused on orienting the head in sagittal plane (pitch) only.^{20,21} The evaluation of the relationship between landmark-based reference planes and NHP on 2D cephalograms showed that FH plane, Krogman-Walker Line, and Palatal plane are the close approximation of NHP.^{4,22,23} However, the reliability and reproducibility of these anatomical reference planes for 3D CBCT orientation has not been evaluated.

With increasing clinical applications of CBCT imaging and growing implications of artificial intelligence (AI) such as automated 3D cephalometrics²⁴ and automated 3D airway analysis¹⁶ in the craniofacial analysis, need for establishment of the correct reference plane for head orientation is required. Therefore, a study was conducted to evaluate the reliability and reproducibility of five methods of orientation of as-received CBCT images in the 3D space using landmark-based craniofacial reference planes.

Materials and Methods

Sample Collection

The study was conducted on CBCT image data obtained from 15 subjects with skeletal malocclusion who were enrolled

in the orthognathic clinic at Division of Orthodontics and Dentofacial Deformities, Centre for Dental Education and Research, All India Institute of Medical Sciences, New Delhi. The mean age of the sample was 21.2 ± 5.8 years (7 males, 8 females). The following inclusion and exclusion criteria were used to select the CBCT images: All the patients were diagnosed to have skeletal malocclusion and potential surgical patients. The CBCT images were screened for adequate field of view (FOV) to include the landmarks required for 3D orientation. The CBCT data was also screened for any artifacts and adequate imaging quality. The patients with cleft lip and palate and hemifacial microsomia or any significant defect that marred the identification of landmarks were excluded. The study was initiated following the approval from the institutional ethics committee.

The sample size was calculated by G*Power software using the data from Pittayapat et al.²¹ For a 95% power, the minimum sample size required was calculated to be nine.

CBCT Acquisition Protocol and Data Storage

The CBCT scans were obtained using i-CAT Next Generation machine (Imaging Sciences International, Hatfield, Pennsylvania, United States) at 120kV, 5mA, 17x22cm FOV, 0.3-mm Voxel and 26-second scanning time. The data were saved in DICOM (Digital Imaging and Communications in Medicine) format with an isometric voxel size of 0.3 mm. The selected datasets were anonymized. Four anonymous datasets were created with the different random sequence. Two orthodontists (R.B., K.S.) separately performed the orientation of anonymized datasets at two different occasions with a time interval of 2 weeks between them.

Orientation Procedure

Dolphin imaging software (version 11.5, Dolphin Imaging & Management Solutions, Canoga Park, California, United States) was used to perform the orientation of 3D CBCT images. Before orientation, the hard tissue volume segmentation of all CBCT scans was done. The gray scale value was standardized between 200 and 400 voxel values.

The reorientation involved correction of head position in all the three planes of space. Five planes for sagittal plane, two for coronal, and two for axial plane were used for correction of head posture (**►Table 1**, **►Fig. 1**). The definition of landmarks used for construction of orientation planes is given in **►Table 2**.

Using these nine reference planes, five methods of orientation (I, II, III, IV, and V) were created with each method having reference planes in the order of sagittal, axial, and coronal axis (**►Table 3**).

Following each instance of orientation, the values of pitch, roll, and yaw were exported from the software and entered into the spreadsheet for further analysis. The changes in the pitch, roll, and yaw measurements represented the degree of rotational changes in coordinate systems of the CBCT in each plane.

Statistical Analysis

The data analyses were performed using SPSS Statistic Software Package (version 17, SPSS, Chicago, Illinois, United States).

Table 1 Three different sets of orientation planes

A. Flexion or extension (FE)
FE1: The Frankfort horizontal plane by connecting right Porion, right and left Orbitale.
FE2: The Frankfort horizontal plane by connecting left Porion, right and left Orbitale
FE3: Opisthion–Maxillion line in lateral view aligned to coincide with axial plane
FE4: Palatal plane by connecting ANS and PNS in lateral view aligned to coincide with axial plane
FE5: Opisthion–ANS plane in lateral view aligned to coincide with axial plane
B. Lateral flexion (LF)
LF1: Transorbital plane (plane passing through right and left Orbitale) in frontal view aligned to coincide with axial plane
LF2: Line passing through medial termini of right and left frontozygomatic suture landmark in frontal view aligned to coincide with axial plane
C. Lateral rotation (LR)
LR1: On top view–the crista galli, cribriform plate mid sagittal structures In frontal view–glabella, ANS were oriented to match with mid-sagittal plane
LR2: Right and left anterior margin of external acoustic meatus (AMEAM) aligned to coincide with coronal plane (line connecting right and left AMEAM)

Intraobserver reliability was calculated by the intraclass correlation coefficient (ICC) for the measurements obtained by each examiner at two different time periods (with an interval of 2 weeks). Interobserver reliability was also assessed using ICC by comparing the measurements obtained by each examiner. ICC values were estimated using a two-way mixed-effects model. Reliability was ranked according to the ICC value and considered excellent when it was above 0.9.

The intra- and interobserver agreement (reliability) was further assessed with the Bland–Altman plot (► Fig. 2).

The paired *t*-test was used to compare the T1 and T2 measurements of the pitch, roll, and yaw orientation methods for each observer. The mean of roll and yaw measurements of same time observation (T1 or T2) were used for comparison purpose since the same method was used more than once. The interobserver error was calculated by comparing the measurements of each method by two observers. The mean of T1 and T2 alignments for each orientation method for each observer was calculated for the comparison purpose. The paired *t*-test was used to compare the measurements between the two observers for the pitch, roll, and yaw orientation methods.

To compare the different orientation methods, the mean of T1 and T2 measurements for each orientation method was calculated by combining the measurements of both observers. The one-way analysis of variance (ANOVA) test was used to compare the five different pitch methods for each observer. The two different roll and yaw orientation methods were compared using paired *t*-test.

The significance level was set at $p < 0.05$ for all the statistical analysis used in this study.

Results

Intra- and Interobserver Reliability

The ICC values were above 0.97 for all the parameters of both intra- and interobserver assessments. These results indicate excellent reliability for both intra- and interobserver assessments.

Intra- and Interobserver Comparison

The intraobserver comparisons showed statistically significant differences in flexion or extension 2 (FE2) ($p = 0.048$) for observer 2 and FE1 ($p = 0.014$), FE2 ($p = 0.000$), lateral flexion 1 (LF1) ($p = 0.001$), and lateral rotation 1 (LR1) ($p = 0.036$) for interobserver comparisons (► Table 4).

Comparison of Different Orientation Methods

The results of the comparison of different pitch, roll, and yaw orientation methods showed statistically insignificant differences among the various methods used for 3D orientation of CBCT image (► Tables 5 and 6).

Bland–Altman Plot

In the pitch orientation, Bland–Altman plot (► Fig. 2) showed greater variation for FE3 and FE4 for both observers. Interobserver variation was high for FE4. For the roll orientation, the Bland–Altman plot (► Fig. 2) showed less variation for both transorbital and transfrontozygomatic suture planes. Anterior margin of external acoustic meatus (AMEAM) line showed the least variation for the yaw orientation (► Fig. 2).

Discussion

The traditional 2D cephalometric analysis involves assessment of the relationship of different skeletal components to each other and in relation to the stable craniofacial reference planes.^{25–27} Evaluation and planning of the position of maxillary/mandibular structures in NHP may provide a more realistic outcome in the clinical scenario. It is essential to set up the 3D coordinate system for the 3D cephalometric measurement and determine the correct pitch, roll, yaw, and translational movements of craniofacial skeletal structures.

The head orientation using cranial reference planes for recording the cephalogram is fundamental to the science of cephalometrics. The validity of cephalometric measurements and analysis is influenced by the reference planes used to reorient the radiograph.²⁸ Acquisition of CBCT in

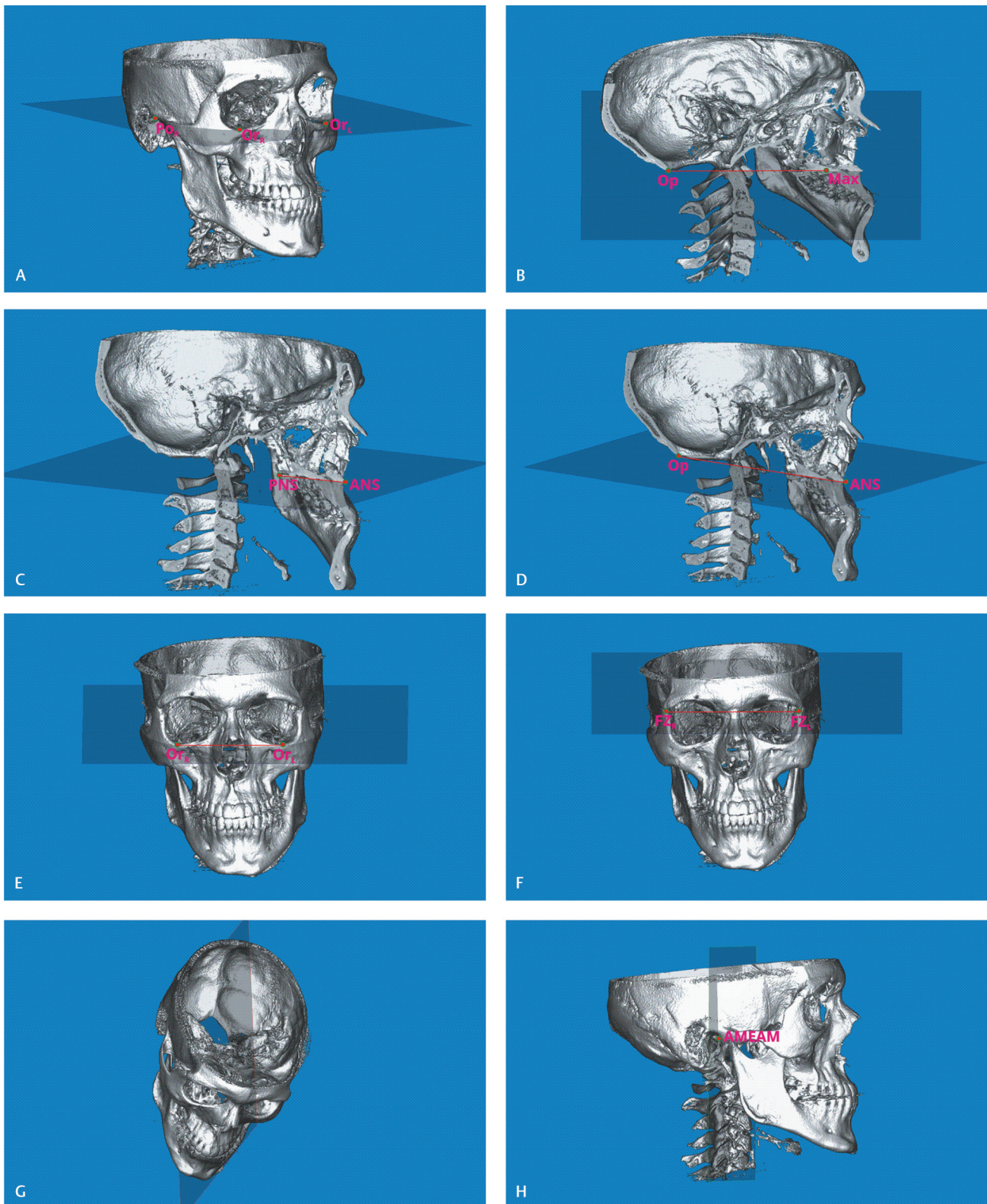


Fig. 1 Orientation planes: (A) FH plane; (B) Opisthion–Maxillion plane; (C) ANS–PNS plane; (D) Opisthion–ANS plane; (E) transorbital plane; (F) transzygomatic suture plane; (G) midsagittal plane passing through mid-sagittal structures; (H) coronal plane passing through AMEAM on both sides. AMEAM, anterior margin of external acoustic meatus; ANS, anterior nasal spine; FH, Frankfort horizontal; PNS, posterior nasal spine.

NHP or a reproducible position has been attempted with the help of additional tools. These techniques have been found impractical since it requires extra instrumentation,

expertise and it is time-consuming. The use of landmark-based reference planes that are the close approximations of NHP has been proven to be a reliable alternative.^{4,29}

Table 2 Definition of landmarks

S. No	Landmark	Definition
1.	Orbitale (Or)	The lowest point on the inferior margin of the orbit
2.	Porion (Po)	The most superior midpoint of the external auditory meatus
3.	Opisthion (Op)	The middle point on the posterior margin of the foramen magnum, opposite to the basion
4.	Maxillion (Max)	A point just below (occasionally above) the key ridge midway between the upper and lower border of the palate in the midsagittal plane
5.	Frontozygomatic suture point (FZS)	The medial point of the orbital rim of the zygomaticofrontal suture
6.	Anterior nasal spine (ANS)	The tip of the bony anterior nasal spine
7.	Posterior nasal spine (PNS)	The tip of the bony posterior nasal spine
8.	Anterior margin of external acoustic meatus (AMEAM)	The anterior most point on the anterior margin of external acoustic meatus

Table 3 Methods used for orientation

Methods	Combination of orientation planes
I	LF1-FE1-LR1
II	FE2-LF2-LR2
III	LF1-LR1-FE3
IV	LF2-LR2-FE4
IV	LF1-LR1-FE5

Abbreviations: FE, flexion or extension; LF, lateral flexion; LR, lateral rotation.

In the current study, the intra- and interobserver reliability of five planes used for pitch correction was excellent (ICC >0.97). The comparison between the different pitch orientation planes showed no significant variation for two observers ($p = 0.613$ and 0.809 for O1 and O2, respectively). The Opisthion–ANS plane (FE5) was used for the first time to orient CBCT and it showed the least variation among the five sagittal planes. This was followed by the FH plane (►Fig. 2). In general terms, FH plane can be a reliable plane for head orientation (CBCT orientation) that corroborates with the previous studies. Lin et al studied the reproducibility and reliability of landmark-based horizontal reference planes. They used the FH plane and lateral semicircular canal plane (LSP) in their study and demonstrated satisfactory results with different FH planes and LSP plane for the orientation of 3D skull models.²⁰ Daboul et al used left and right Porion (Po) and left Orbitale (Or) on the multiplanar reconstruction view for defining the FH plane and showed excellent intra- and interexaminer reproducibility of FH planes in magnetic resonance imaging.³⁰

A plane can be constructed using two or many landmarks. The number of landmarks used to define a plane and the distance between them may influence the construction of

craniofacial reference plane. Each landmark possesses some uncertainty in terms of their accurate identification. When the number of landmarks increase, the plotting error for each landmark may add up and contribute to the overall variation. Similarly, the distance between the landmarks may influence the construction of a plane. The plane constructed using two landmarks with the shorter distance between them is affected more by the landmark plotting error. Accordingly, the palatal plane, which has closest landmarks among the planes used in this study, showed larger variation for both intra- and interobserver comparison.

It is also important to note that the ease of identification of certain landmarks like ANS and PNS is hampered in patients with cleft lip and palate that may require use of alternative landmarks. Although the Opisthion–ANS plane (FE5) showed the least variation, one should be careful while using this plane for orientation in facial asymmetry cases.

The FH plane (FE2) defined using the combination of three landmarks showed better intra- and interobserver agreement than the Opisthion–Maxillion plane (FE3) and Palatal plane (FE4) that were defined using only two landmarks. This may be due to the structural complexity and lack of proper definition of landmarks used to define these planes. The Maxillion landmark is not well defined in the 3D volume rendered image when compared with the other landmarks used, which may lead to a subjective error. Hence, in this study, it is observed that the influence of multiple landmarks on defining a plane is not substantial. This indicates that the use of well-defined landmarks for defining the planes is more important than the distance between the landmarks.

The intraobserver error was statistically insignificant for roll. The interobserver error was statistically significant for the transorbital plane (LF1). However, the error is within the acceptable limits. The interplane comparison (LF1 versus LF2) showed statistically insignificant differences between both the planes. Landmarks used in both planes are least affected by the facial deformities. Both the methods can be used alternatively since the variation in both the methods is minimal (►Fig. 2).

There are no studies reported in literature evaluating the use of reference planes for yaw orientation. In this current study, the intraobserver agreement for the yaw orientation planes was excellent. The midsagittal plane (LR1) showed statistically significant interobserver error but within an acceptable limit (►Fig. 2). The plane constructed using AMEAM (LR2) showed a less inter- and intraobserver difference than the midsagittal plane. For the alignment of yaw, the midsagittal structures are viewed from the top. Since there is no landmark involved and due to the complex midsagittal anatomical structures, there may be subjective variation in the selection of midsagittal line. This may account to the larger variation observed in midsagittal pane (LR1) when compared with AMEAM plane (LR2).

It has been shown that the NHP is subject to change with time and after the orthognathic surgery.^{31,32} Hence, in such situations the landmark-based orientation method may be a better alternative for the long-term evaluation.

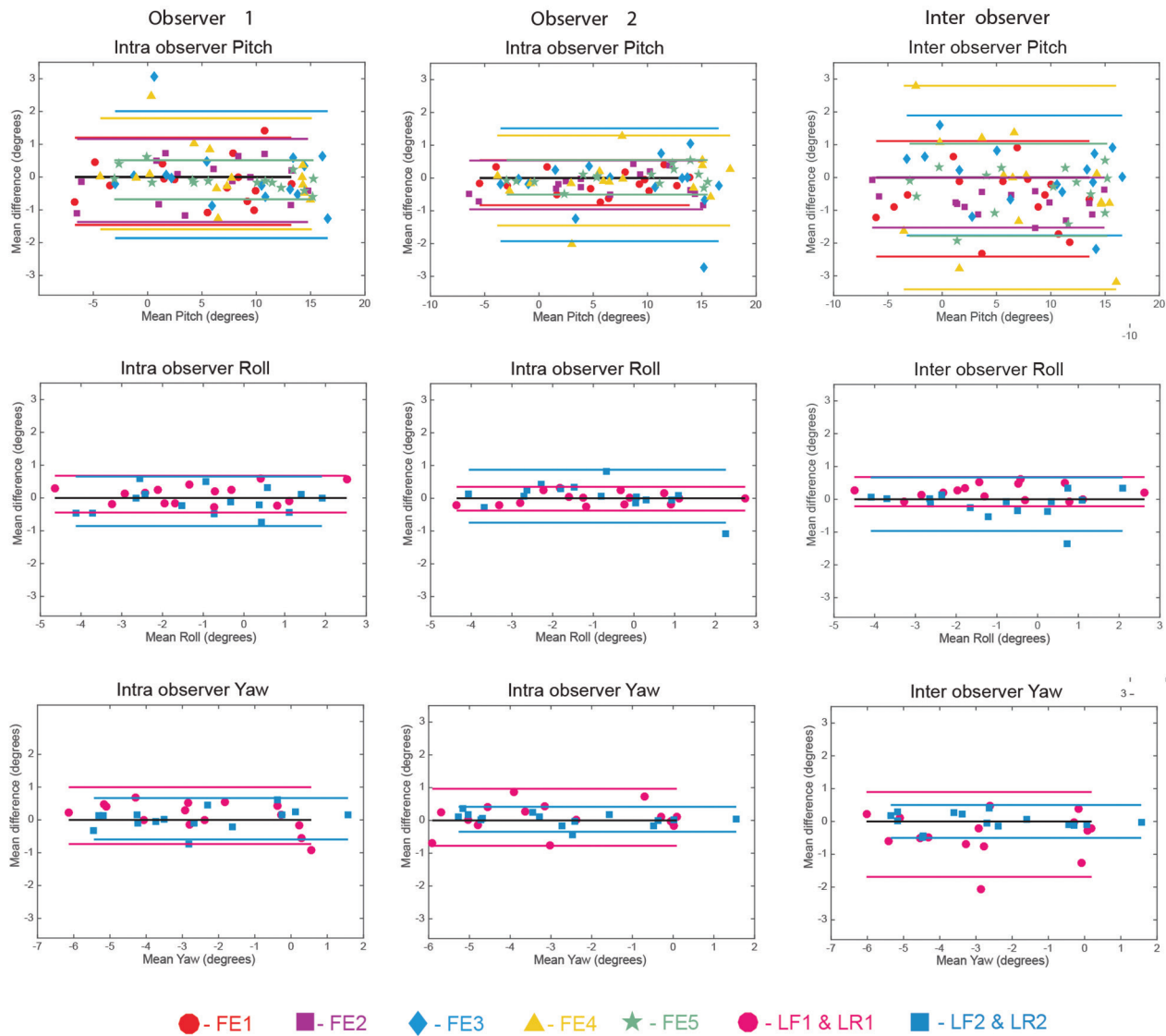


Fig. 2 Bland–Altman plots of the intra- and interobserver comparison for pitch, roll, and yaw. All the measurements errors are shown in degree. Plots show the mean and ± 1.96 standard deviation reference lines for each plane. FE, flexion or extension; LF, lateral flexion; LR, lateral rotation.

Table 4 Intra- and interobserver comparisons

	n	Observer 1			Observer 2			Interobserver			
		Mean difference	SE	p-Value	Mean difference	SE	p-Value	Mean difference	SD	SE	p-Value
FE1	15	-0.13	0.17	0.472	-0.14	0.09	0.137	-0.65	0.90	0.23	0.014 ^a
FE2	15	-0.10	0.17	0.548	-0.21	0.10	0.048 ^a	-0.76	0.39	0.10	0.000 ^a
FE3	15	0.07	0.25	0.776	-0.21	0.23	0.378	0.06	0.93	0.24	0.802
FE4	15	0.10	0.22	0.659	-0.08	0.18	0.678	-0.31	1.58	0.41	0.467
FE5	15	-0.08	0.08	0.317	0.02	0.07	0.763	-0.38	0.72	0.19	0.062
LF1	15	0.12	0.07	0.130	-0.01	0.05	0.820	0.23	0.23	0.06	0.001 ^a
LF2	15	-0.10	0.10	0.324	0.06	0.11	0.561	-0.15	0.42	0.11	0.184
LR1	15	0.13	0.11	0.268	0.10	0.11	0.414	-0.40	0.66	0.17	0.036 ^a
LR2	15	0.04	0.08	0.669	0.03	0.05	0.499	0.00	0.26	0.07	0.996

Abbreviations: FE, flexion or extension; LF, lateral flexion; LR, lateral rotation; SD, standard deviation; SE, standard error.

^aSignificant difference.

Table 5 Comparison of different orientation methods using one-way ANOVA test

	<i>n</i>	Parameter	Mean	SD	<i>p</i> -Value
Observer 1	15	FE1	4.82	6.14	0.613
	15	FE2	5.37	6.59	
	15	FE3	8.03	6.71	
	15	FE4	7.02	6.40	
	15	FE5	7.44	6.59	
Observer 2	15	FE1	5.47	6.20	0.809
	15	FE2	6.14	6.73	
	15	FE3	7.96	6.97	
	15	FE4	7.32	6.96	
	15	FE5	7.82	6.53	

Abbreviations: ANOVA, analysis of variance; FE, flexion or extension; SD, standard deviation.

Table 6 Comparison of different orientation methods using paired *t*-test

	<i>n</i>	Parameter	Mean difference	SE	<i>p</i> -Value
Observer 1	15	LF1-LF2	-0.27	0.20	0.195
	15	LR1-LR2	0.20	0.25	0.451
Observer 2	15	LF1-LF2	0.12	0.15	0.455
	15	LR1-LR2	-0.20	0.22	0.386

Abbreviations: FE, flexion or extension; LF, lateral flexion; LR, lateral rotation; SE, standard error.

The major implications of this study are standardization of CBCT image for orthognathic surgical planning for more realistic treatment simulations, growth assessment, short-term and long-term evaluation of treatment outcomes, and AI technology in craniofacial imaging. The rapid progress in AI technology and with its expanding role in orthodontics and surgical discipline requires the establishment of a reliable and reproducible orientation plane, which can be effectively incorporated in future AI algorithms.

The variation in head positioning during CBCT imaging has not been reported in literature in three dimensions. The present study showed major variation in sagittal view than the axial and coronal. The sagittal plane is most commonly used for orienting the image for the purpose of treatment planning and evaluation. The methods described in the present study included the planes that involves both the maxillary and cranial landmarks, and exclusive cranial landmarks only. This may help to orient the CBCT in situations like cases with severe facial deformity, and the non-availability of cranial landmarks, like Nasion, Sella, due to the limited FOV. Another major advantage of planes used in this study is that most of the planes can be located in the CBCT obtained using medium FOV, thereby reducing the radiation exposure.

The limitation of this study is that these planes are not validated in severe craniofacial deformity cases and use of a relatively smaller sample size due to the ethical concerns arising from radiation exposure. The validity of these reference planes on complex malocclusion and facial deformities needs to be evaluated in future studies using

larger sample size. The future prospective studies should be designed by strictly following ALARA principle (As Low As Reasonably Achievable) and include radiologist as an observer.

Conclusion

Three-dimensional orientation using anatomical landmarks-based planes is reproducible. The nine planes used in this study for 3D orientation of CBCT image showed good reproducibility. The significance of identification of these planes is that they can be used alternatively when one or more landmarks are not available due to any deformity or artifacts or FOV restrictions. Among the five planes evaluated for the pitch correction, Opisthion-ANS plane showed the least variation followed by the FH plane. For the roll and yaw alignment, transzygomatic suture plane and AMEAM line showed minimal variation, respectively. The impact of variation in patient positioning during CBCT imaging was high for pitch followed by yaw and roll.

Authors' Contributions

R.B.: Concept and design of the study, conducted the study, literature review, collection of data, data analysis, writing and revision of manuscript. O.P.K.: Concept and design of the study, provided samples, interpretation of data, and writing of manuscript. K.S.: Data marking, interpretation of data, and writing and revision of the manuscript. B.C.N.: Examined the concept, assisted in review of the study, data analysis, and writing of the manuscript.

Funding

None.

Conflict of Interest

None declared.

References

- 1 Xia JJ, McGrory JK, Gateno J, et al. A new method to orient 3-dimensional computed tomography models to the natural head position: a clinical feasibility study. *J Oral Maxillofac Surg* 2011;69(3):584–591
- 2 Leung MY, Lo J, Leung YY. Accuracy of different modalities to record natural head position in 3 dimensions: a systematic review. *J Oral Maxillofac Surg* 2016;74(11):2261–2284
- 3 Cassi D, De Biase C, Tonni I, Gandolfini M, Di Blasio A, Piancino MG. Natural position of the head: review of two-dimensional and three-dimensional methods of recording. *Br J Oral Maxillofac Surg* 2016;54(3):233–240
- 4 Barbera AL, Sampson WJ, Townsend GC. An evaluation of head position and craniofacial reference line variation. *Homo* 2009;60(1):1–28
- 5 Moorrees CF. Natural head position—a revival. *Am J Orthod Dentofacial Orthop* 1994;105(5):512–513
- 6 Vale F, Scherzberg J, Cavaleiro J, et al. 3D virtual planning in orthognathic surgery and CAD/CAM surgical splints generation in one patient with craniofacial microsomia: a case report. *Dental Press J Orthod* 2016;21(1):89–100
- 7 Uribe F, Janakiraman N, Shafer D, Nanda R. Three-dimensional cone-beam computed tomography-based virtual treatment planning and fabrication of a surgical splint for asymmetric patients: surgery first approach. *Am J Orthod Dentofacial Orthop* 2013;144(5):748–758
- 8 Cevidanes LH, Bailey LJ, Tucker GR Jr, et al. Superimposition of 3D cone-beam CT models of orthognathic surgery patients. *Dentomaxillofac Radiol* 2005;34(6):369–375
- 9 Cevidanes LH, Bailey LJ, Tucker SF, et al. Three-dimensional cone-beam computed tomography for assessment of mandibular changes after orthognathic surgery. *Am J Orthod Dentofacial Orthop* 2007;131(1):44–50
- 10 Lagravère MO, Major PW. Proposed reference point for 3-dimensional cephalometric analysis with cone-beam computerized tomography. *Am J Orthod Dentofacial Orthop* 2005;128(5):657–660
- 11 Olszewski R, Zech F, Cosnard G, Nicolas V, Macq B, Reyhler H. Three-dimensional computed tomography cephalometric craniofacial analysis: experimental validation in vitro. *Int J Oral Maxillofac Surg* 2007;36(9):828–833
- 12 Swennen GR, Schutyser F. Three-dimensional cephalometry: spiral multi-slice vs cone-beam computed tomography. *Am J Orthod Dentofacial Orthop* 2006;130(3):410–416
- 13 Swennen GRJ, Schutyser F, Barth E-L, De Groeve P, De Mey A. A new method of 3-D cephalometry Part I: the anatomic Cartesian 3-D reference system. *J Craniofac Surg* 2006;17(2):314–325
- 14 Pittayapat P, Limchaichana-Bolstad N, Willems G, Jacobs R. Three-dimensional cephalometric analysis in orthodontics: a systematic review. *Orthod Craniofac Res* 2014;17(2):69–91
- 15 Ruellas AC, Tonello C, Gomes LR, et al. Common 3-dimensional coordinate system for assessment of directional changes. *Am J Orthod Dentofacial Orthop* 2016;149(5):645–656
- 16 Neelapu BC, Kharbanda OP, Sardana V, et al. A pilot study for segmentation of pharyngeal and sino-nasal airway subregions by automatic contour initialization. *Int J CARS* 2017;12(11):1877–1893
- 17 Damstra J, Fourie Z, Ren Y. Simple technique to achieve a natural position of the head for cone beam computed tomography. *Br J Oral Maxillofac Surg* 2010;48(3):236–238
- 18 de Paula LK, Ackerman JL, Carvalho F de AR, Eidson L, Cevidanes LH. Digital live-tracking 3-dimensional minisensors for recording head orientation during image acquisition. *Am J Orthod Dentofacial Orthop* 2012;141(1):116–123
- 19 Hsung TC, Lo J, Li TS, Cheung LK. Recording of natural head position using stereophotogrammetry: a new technique and reliability study. *J Oral Maxillofac Surg* 2014;72(11):2256–2261
- 20 Lin HH, Chuang YF, Weng JL, Lo LJ. Comparative validity and reproducibility study of various landmark-oriented reference planes in 3-dimensional computed tomographic analysis for patients receiving orthognathic surgery. *PLoS One* 2015;10(2):e0117604
- 21 Pittayapat P, Jacobs R, Bornstein MM, et al. Three-dimensional Frankfort horizontal plane for 3D cephalometry: a comparative assessment of conventional versus novel landmarks and horizontal planes. *Eur J Orthod* 2018;40(3):239–248
- 22 Madsen DP, Sampson WJ, Townsend GC. Craniofacial reference plane variation and natural head position. *Eur J Orthod* 2008;30(5):532–540
- 23 Lundström A, Lundström F. The Frankfort horizontal as a basis for cephalometric analysis. *Am J Orthod Dentofacial Orthop* 1995;107(5):537–540
- 24 Gupta A, Kharbanda OP, Sardana V, Balachandran R, Sardana HK. Accuracy of 3D cephalometric measurements based on an automatic knowledge-based landmark detection algorithm. *Int J CARS* 2016;11(7):1297–1309
- 25 Downs WB. Variations in facial relationships; their significance in treatment and prognosis. *Am J Orthod* 1948;34(10):812–840
- 26 Steiner CC. Cephalometrics for you and me. *Am J Orthod* 1953;39(10):729–755
- 27 Ricketts RM. Cephalometric analysis and synthesis. *Angle Orthod* 1961;31(3):141–156
- 28 Lagravère MO, Hansen L, Harzer W, Major PW. Plane orientation for standardization in 3-dimensional cephalometric analysis with computerized tomography imaging. *Am J Orthod Dentofacial Orthop* 2006;129(5):601–604
- 29 Barbera AL, Sampson WJ, Townsend GC. Variation in natural head position and establishing corrected head position. *Homo* 2014;65(3):187–200
- 30 Daboul A, Schwahn C, Schaffner G, et al. Reproducibility of Frankfort horizontal plane on 3D multi-planar reconstructed MR images. *PLoS One* 2012;7(10):e48281
- 31 Cooke MS. Five-year reproducibility of natural head posture: a longitudinal study. *Am J Orthod Dentofacial Orthop* 1990;97(6):489–494
- 32 Cho D, Choi DS, Jang I, Cha BK. Changes in natural head position after orthognathic surgery in skeletal Class III patients. *Am J Orthod Dentofacial Orthop* 2015;147(6):747–754