




# Granulomatosis with Polyangiitis Presenting as a Renal Mass: A Scarce Case Report with a Review of the Literature

Manjeet Kumar<sup>1</sup>  Kailash Chander Barwal<sup>1</sup> Sunish Sharma<sup>2</sup> Sanjeev Chauhan<sup>1</sup> Pamposh Raina<sup>1</sup>

<sup>1</sup> Department of Urology, IGMC, Shimla, Himachal Pradesh, India

<sup>2</sup> Department of Pathology, IGMC, Shimla, Himachal Pradesh, India

Address for correspondence Manjeet Kumar, MBBS, MS General Surgery, MCH Urology, Department of Urology, IGMC Shimla, Himachal Pradesh, 171001, India (e-mail: manjeetkumar.1014@gmail.com).

Ann Natl Acad Med Sci (India) 2023;59:55–59.

## Abstract

Wegener granulomatosis (WG) now known as granulomatosis with polyangiitis (GPA) is an uncommon autoimmune disorder of undivulged etiology affecting the respiratory tract including paranasal sinuses, nasal cavity, lungs, and kidneys predominantly. GPA presenting as a solitary renal mass is rarely seen. We present a case report of a 27-year-old female presenting with a right renal mass along with pain, low-grade fever, and arthralgia. Computed tomography scan of the abdomen revealed a hypodense low attenuated renal mass with indistinct margins. Ultrasound-guided biopsy revealed features typical of GPA. She was started on oral steroids (prednisolone 40 mg) and azathioprine. She developed pain, vomiting, and diarrhea after starting treatment with azathioprine. Azathioprine was stopped and rituximab 1 g weekly was started for 4 weeks followed by 500 mg 6 monthly injections. She got symptomatic relief at 4 weeks with a diminution of renal mass at 6 months follow-up. We report this rare entity of WG presenting as renal mass. Suspecting and diagnosing renal mass as a part of GPA prevented us from undertaking unnecessary surgical treatment in this patient. Medical treatment with steroids and rituximab is effective in inducing remission and maintenance.

## Keywords

- ▶ Wegener granulomatosis
- ▶ granulomatosis with polyangiitis
- ▶ immunosuppressive therapy

## Introduction

Wegener granulomatosis (WG) now known as granulomatosis with polyangiitis (GPA) was first described by Friedrich

*Granulomatosis with polyangiitis is uncommon autoimmune small to medium vessel disease affecting kidney frequently. GPA presenting as solitary renal mass is very rarely seen. Early diagnosis of GPA on basis of clinical features and radiological study like CT scan is crucial. Imaging guided biopsy is paramount for making a diagnosis of GPA. Diagnosing GPA could prevent surgery as medical treatment is effective. We highlight our rare presentation of GPA with renal mass and its medical management.*

Wegener in 1936. It has characteristics of necrotizing granulomatous inflammation and pauci-immune vasculitis in small- to medium-sized blood vessels. Involvement of the kidney is common, which presents as proteinuria, hematuria (microscopic), and hypertension.<sup>1,2</sup> A very rare presentation of GPA is solitary renal mass or multiple renal masses. Differential diagnoses are renal tumors, abscesses, and lymphomas. Solitary renal mass is rarely a presenting feature of GPA and is reported in only eight cases to date. Treatment is cyclophosphamide, azathioprine, rituximab, and glucocorticoids. Most patients were diagnosed after nephrectomy; however, we suspected GPA and managed conservatively

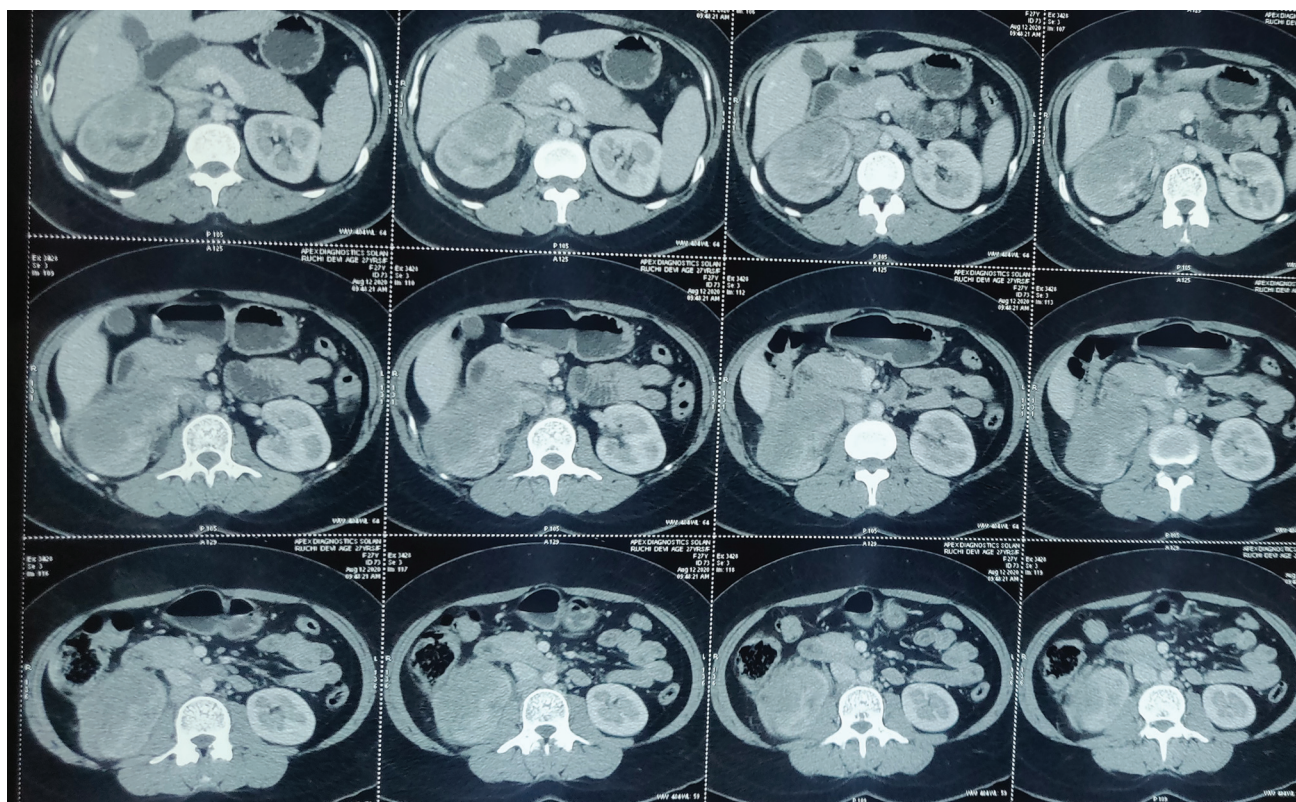
article published online  
February 16, 2023

DOI <https://doi.org/10.1055/s-0042-1760352>.  
ISSN 0379-038X.

© 2023. National Academy of Medical Sciences (India). All rights reserved.

This is an open access article published by Thieme under the terms of the Creative Commons Attribution-NonDerivative-NonCommercial-License, permitting copying and reproduction so long as the original work is given appropriate credit. Contents may not be used for commercial purposes, or adapted, remixed, transformed or built upon. (<https://creativecommons.org/licenses/by-nc-nd/4.0/>)

Thieme Medical and Scientific Publishers Pvt. Ltd., A-12, 2nd Floor, Sector 2, Noida-201301 UP, India



**Fig. 1** Axial contrast-enhanced computed tomography scan showing ill-defined heterogeneous mass occupying in mid and lower pole of the right kidney with perinephric stranding.

with rituximab, and steroids after diagnosing with ultrasound-guided biopsy. This article aims to present this rare entity and review the literature.

### Case Summary

A 27-year-old female presented with mild flank pain, loss of appetite, and low-grade fever for 3 months. On examination, her vitals were as follows: pulse was 84/min, blood pressure 108/70, and a lump was palpable in the right lumbar region extending into the right hypochondrium and umbilical regions. Investigations revealed hemoglobin 9.5 g/dL, urea 25 mg/dL, creatinine 0.8 mg/dL, total leucocyte count 10,300, C-reactive protein (CRP) 127 mg/L, and erythrocyte sedimentation rate 57 mm, and urine culture was sterile.

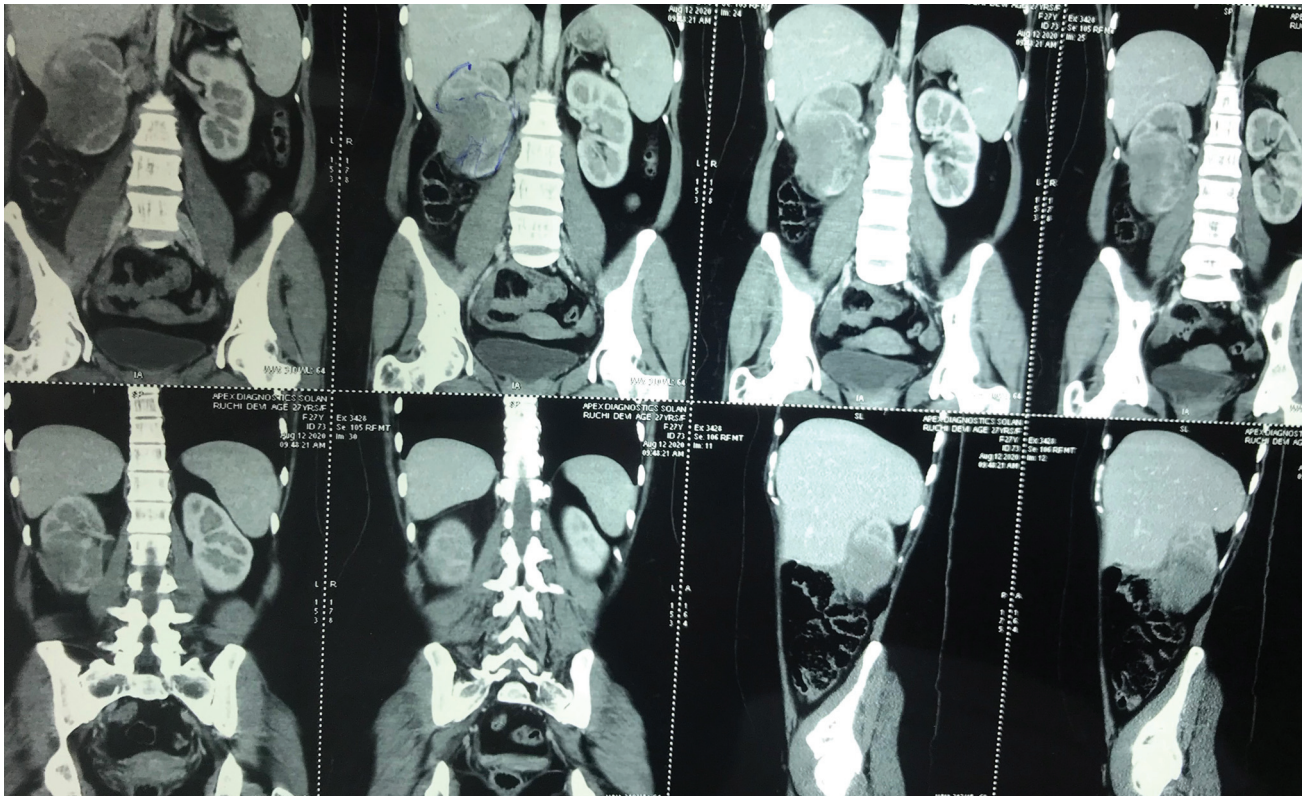
Ultrasound kidney, ureter, and bladder showed a heterogeneous hypoechoic mass of size  $8.6 \times 7.8 \times 5.2$  involving the lower and mid pole of the right kidney that was displacing the pelvic calyceal system. Contrast-enhanced computed tomography (CT) scan was suggestive of an ill-defined mass  $8.6 \times 7.8 \times 5.2$  cm in the lower and mid pole displacing the pelvic calyceal system toward the upper pole, with minimal internal vascularity. Mass had unclear borders and was infiltrating perinephric fat and duodenum. Contrast enhancement of mass was 50 to 60 Hounsfield unit, which was as low compared to normal kidney parenchyma. The heterogeneous perinephric fat stranding was seen. Multiple lymph nodes were enlarged predominantly para-

aortic, and aortocaval, the largest measuring  $28 \times 32$  mm (**→ Figs. 1–3**).

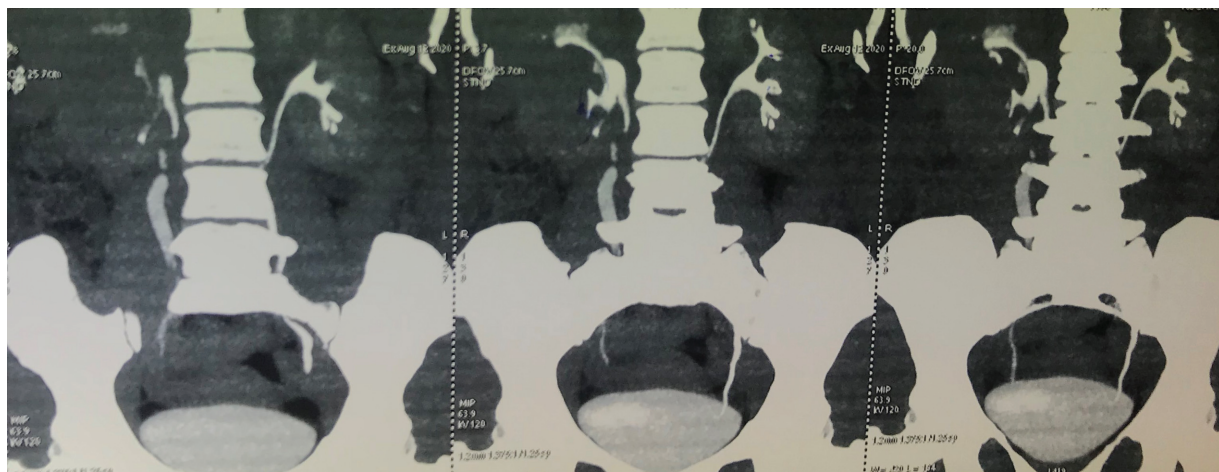
Since the radiological features were unlikely of renal cell carcinoma (RCC), an ultrasound-guided biopsy was planned to rule out RCC, renal abscess, lymphomas, or tuberculosis. Biopsy revealed inflammatory infiltrate with foci of neutrophilic micro-abscess, epithelioid cells granuloma, and multinucleated giant cells spread among lymphocytes and plasma cells along with neutrophils. The inflammatory infiltrates comprised patchy foci of neutrophilic microabscesses, occasionally scattered epithelioid cells with epithelioid cell granuloma (**→ Figs. 4 and 5**).

Cytoplasmic-antineutrophil cytoplasmic antibody was 1:290 with strongly positive anti-PR3, suggesting WG. On systemic examination, she had sinusitis with no involvement of respiratory tract, lungs, eyes, ear, and skin. She was prescribed azathioprine and steroids (prednisolone 60 mg). She was counselled regarding the disease and prednisolone 60 mg was started with weekly tapering of steroids (5mg/week till the 5 mg dose was achieved. Prednisolone 5 mg continued for 1 year. Azathioprine 50 mg twice daily was started; however, she developed abdominal pain, diarrhea, and vomiting after 2 weeks. Azathioprine was stopped and rituximab was started 1 g weekly for 4 weeks then 500 mg every 6 months. On follow-up, symptomatic resolution was seen with a resolution of renal mass at 6 months, and her full blood count, renal function, and CRP returned to normal.





**Fig. 2** Coronal sections of the contrast-enhanced computed tomography abdomen show heterogenous mass mid and lower pole with ill-defined margins, perinephric stranding, and involving duodenum.



**Fig. 3** Urography films of contrast-enhanced computed tomography abdomen showing heterogenous mass mid and lower pole with ill-defined margins. For Peer Review pushing calyces away without involving them.

## Discussion

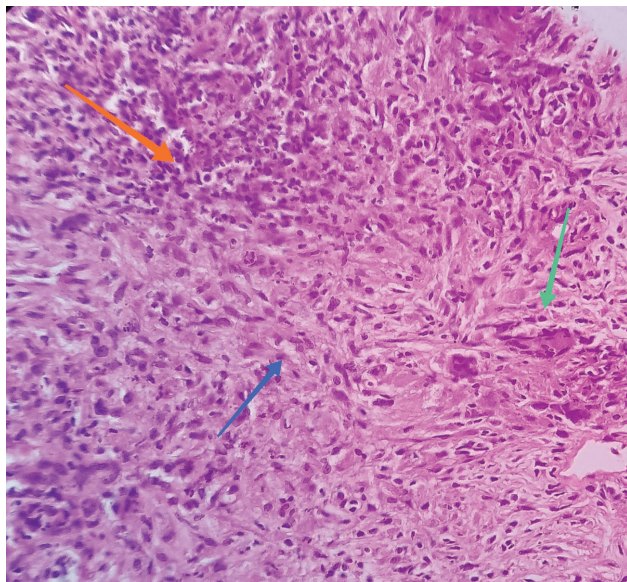
WG is necrotizing granulomatous vasculitis of unknown etiology involving the respiratory tract, lungs, skin, eyes, kidneys, etc. It has varied presentations ranging from mild-to-severe illness. It is small-to-medium vessel vasculitis with necrotizing granulomatous inflammatory nodules involving the respiratory tract, and kidneys. GPA initially involves the kidney in 20% of cases, although subsequent involvement is seen in 80% of cases. Ocular manifestations of WG are seen in 50 to 60 % of cases. It may occur secondary to granulomatous

sinusitis or due to focal vasculitis in the form of nasolacrimal duct obstruction, proptosis, conjunctivitis, episcleritis, scleritis, corneoscleral ulceration, uveitis, and optic neuritis. Kidney involvement is seen as microhematuria, proteinuria, and renal failure. Microscopically, it is seen as patchy necrotizing glomerulonephritis.<sup>1,2</sup>

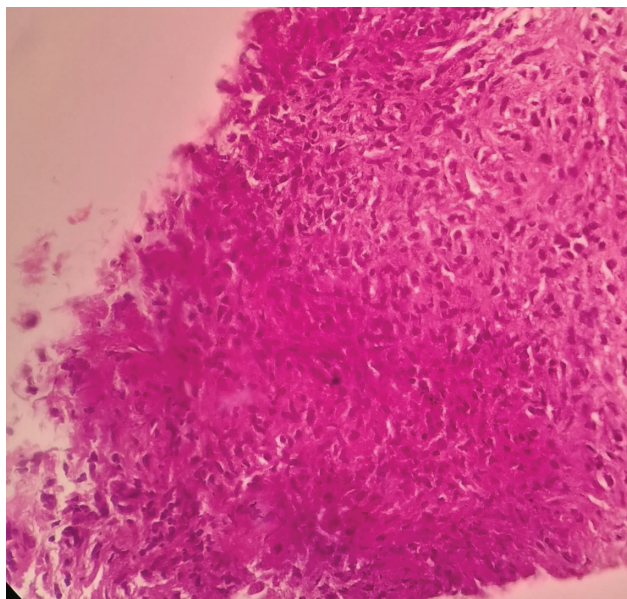
Renal mass is a rare presentation of GPA and its clinical and radiologic manifestations are similar to a renal abscess, tumor, or an inflammatory process.<sup>3</sup>

Maguire et al reported one patient had renal mass out of 31 patients presenting with GPA.<sup>4</sup>





**Fig. 4** Histopathology showing areas of necrosis with a collection of neutrophils (orange arrow), few epithelioid cell granulomas (blue arrow), and occasional giant cells (green arrow) (400X, hematoxylin and eosin).



**Fig. 5** Histopathology showing areas of necrosis with a collection of neutrophils, few epithelioid cell granulomas, and occasional giant cells (400X, hematoxylin and eosin).

Frigui et al<sup>5</sup> et al in a review of literature reported renal involvement as renal mass in 13 patients. He concluded that imaging alone cannot differentiate between renal tumors and mass due to WG. Villa-Forte et al<sup>6</sup> reported a case of simultaneous development of RCC and GPA renal lesions and proposed renal biopsy to confirm the diagnosis of suspected GPA and repetition of imaging studies to determine the resolution of mass lesions after appropriate treatment. He reported renal lesions in a WG along with RCC.

GPA presenting with solitary renal mass is seen in only eight case reports. Three patients were diagnosed with GPA

after nephrectomy for renal mass and one after partial nephrectomy for renal mass. Four patients were diagnosed with percutaneous biopsy and managed conservatively.<sup>7-15</sup>

Pathologic analysis of the masses in these cases revealed them to be inflammatory masses or pseudo tumors or RCC. It is prudent to differentiate RCC from the inflammatory mass. Taking a meticulous history and physical examination and high clinical suspicion is of great importance to prevent unnecessary interventions and delay treatment.

Yamamoto et al reported 24 cases of renal mass in GPA with solitary lesions seen in 62%, (13/21), both kidneys having multiple masses in 28.5% (6/21), and unilateral kidneys having multiple masses. The finding was confirmed with a CT scan in 15 patients. The most common finding was hypovascular mass with undemarcated margins. Other investigations that can help differentiate could be magnetic resonance imaging and positron emission tomography scans. Other sites involved were seen in 50% of cases including the upper respiratory tract, ears, and lungs.

Immunosuppressive therapy, that is, primarily azathioprine, cyclophosphamide, rituximab, and steroids, has markedly improved survival and remission rates in GPA patients. However, the therapy with cyclophosphamide is associated with significantly increased side effects and risk of urinary bladder cancer development. Rituximab and azathioprine are fewer toxic alternatives to cyclophosphamide.

In our case, a history of fever, arthralgia, flank pain, and atypical features on CT scan like hypovascular mass with indistinct borders, peritumoral stranding, and lymphadenopathy were crucial for diagnosis. Ultrasound-guided biopsy clinched the diagnosis. In addition, antineutrophil cytoplasmic antibodies and anti-PR3 antibodies were positive. She was prescribed steroids and rituximab and she responded dramatically. Renal biopsy, although paramount, should not delay treatment if other features suggest GPA. Diagnosis of WG is critical as surgery could be detrimental in these patients with delay in treatment.

## Conclusions

In case of hypovascular renal mass in young patients with suggestive history, a clinician should keep GPA in mind as early diagnosis can make a difference. Medical treatment with steroids and rituximab is effective in inducing remission and maintenance.

### Conflict of Interest

None declared.

## References

- Hoffman GS, Kerr GS, Leavitt RY, et al. Wegener granulomatosis: an analysis of 158 patients. *Ann Intern Med* 1992;116(06): 488-498
- Haynes BF, Fishman ML, Fauci AS, Wolff SM. The ocular manifestations of Wegener's granulomatosis. Fifteen years experience and review of the literature. *Am J Med* 1977;63(01):131-141
- Mohammadi Sichani M, Hadi M, Talebi A, Khalighinejad P. Renal solid mass as a rare presentation of Wegener's granulomatosis: a case report. *Case Rep Urol* 2012;2012:793014

- 4 Maguire R, Fauci AS, Doppman JL, Wolff SM. Unusual radiographic features of Wegener's granulomatosis. *AJR Am J Roentgenol* 1978; 130(02):233–238
- 5 Frigui M, Ben Hmida M, Kechaou M, Jlidi R, Bahloul Z. Wegener's granulomatosis presenting as multiple bilateral renal masses: case report and literature review. *Rheumatol Int* 2009;29(06): 679–683
- 6 Villa-Forte A, Hoffman GS. Wegener's granulomatosis presenting with a renal mass. *J Rheumatol* 1999;26(02):457–458
- 7 Smith DJ, Milroy CM, Chapple CR. An unusual renal mass? Wegener's granulomatosis. *Br J Urol* 1993;72(06): 980–981
- 8 Boubenider SA, Akhtar M, Nyman R. Wegener's granulomatosis limited to the kidney as a masslike lesion. *Nephron J* 1994;68(04): 500–504
- 9 Roussou M, Dimopoulos SK, Dimopoulos MA, Anastasiou-Nana MI. Wegener's granulomatosis presenting as a renal mass. *Urology* 2008;71(03):547.e1–547.e2
- 10 Tatsis E, Reinhold-Keller E, Steindorf K, Feller AC, Gross WL. Wegener's granulomatosis associated with renal cell carcinoma. *Arthritis Rheum* 1999;42(04):751–756
- 11 Fairbanks KD, Hellmann DB, Fishman EK, Ali SZ, Stone JH. Wegener's granulomatosis presenting as a renal mass. *AJR Am J Roentgenol* 2000;174(06):1597–1598
- 12 Schapira HE, Kapner J, Szporn AH. Wegener granulomatosis presenting as renal mass. *Urology* 1986;28(04):307–309
- 13 Krambeck AE, Miller DV, Blute ML. Wegener's granulomatosis presenting as renal mass: a case for nephron-sparing surgery. *Urology* 2005;65(04):798
- 14 Negi A, Camilleri JP, Matthews PN, Crane MD. Wegener's granulomatosis presenting as a disappearing renal mass. *Rheumatology (Oxford)* 2006;45(12):1554
- 15 Yamamoto T, Tkahata K, Kamei S, Ishikawa M, Matsumoto D, Suzuki K. Granulomatosis with polyangiitis presenting as a solitary renal mass: a case report with imaging and literature review. *Radiol Case Rep* 2021;16(03):736–741