

Gorlin–Goltz Syndrome with Multidisciplinary Approach of Treatment

Jayachandran Sadaksharam¹ Amutha Velappan Annapoorni¹

¹Department of Oral Medicine and Radiology, Tamil Nadu Government Dental College and Hospital, Chennai, Tamil Nadu, India

Address for correspondence Jayachandran Sadaksharam, MDS, PhD, MBA, MAMS, FDS, RCPS (Glasgow), Department of Oral Medicine and Radiology, Tamil Nadu Government Dental College and Hospital (Affiliated to Tamil Nadu Dr. M. G. R. Medical University), Chennai 600003, Tamil Nadu, India (e-mail: drsjayachandranmds@yahoo.com).

Ann Natl Acad Med Sci (India) 2019;55:213–218

Abstract

Keywords

- ▶ Gorlin–Goltz syndrome
- ▶ multiple odontogenic keratocyst syndrome
- ▶ nevoid basal cell carcinoma syndrome
- ▶ Gorlin’s syndrome

Gorlin–Goltz syndrome, is an uncommon genetic condition characterized by the presence of multiple odontogenic keratocysts of jaws along with several other abnormal, cutaneous, ophthalmic, and osseous displays. This syndrome is also acknowledged by various names, such as nevoid basal cell carcinoma syndrome, jaw cyst, and bifid rib syndrome. This article illustrates about the clinical, radiological, and histological diagnostic findings and the multidisciplinary approach of treatment given to one such rare case of Gorlin–Goltz syndrome.

Introduction

Gorlin–Goltz syndrome is an autosomal dominant disorder with high degree of penetrance and variable expressivity. The prevalence ranges from 1/57,000 to 1/256,000, with an equal predisposition to males and females in the ratio of 1:1.¹ For a diagnosis to be established, there should be two major and one minor criterion or one major and three minor criteria. Early diagnosis and treatment planning are mandatory as it may develop to more aggressive basal cell carcinomas (BCCs). The treatment always relies on multidisciplinary approach due to the involvement of various other systemic disorders.

Case Report

A 50-year-old female patient, who had ulcer on the scalp and was diagnosed as BCC by the Surgical Oncology Department, was referred to the Department of Oral Medicine and Radiology at Tamil Nadu Government Dental College and Hospital for a painless swelling in right side of mandible which was noticed during the treatment period. On eliciting the history of presenting illness, patient noticed the swelling on the

mandible 5 months before which was insidious in onset and nonprogressive in nature. Her medical history revealed that she was on hypothyroid medication for past 1 year and her family history was noncontributory. On general examination, patient was calm, cooperative, moderately built, and nourished, her weight was 61 kg and height was approximately around 162 cm. No signs of anemia, icterus, cyanosis, clubbing and pedal edema were present. On clinical examination, facial asymmetry was present due to the presence of swelling on right side of the mandible with slight mandibular prognathism. An ulcer approximately of size 5 cm × 5 cm with raised borders was present on scalp covered by granulation tissue. Multiple cutaneous nevus was present on the face which was diagnosed as compound nevus by the dermatology department. Intraoral examination revealed that upper and lower jaws were partially edentulous and swelling was present on the right and left side of the mandible with obliteration of buccal vestibule from 44 to 47 and from 35 to 37, respectively. The overlying mucosa was normal, and the teeth present were periodontally compromised. On palpation, it was slightly tender, cystic in consistency, and buccal cortical plate expansion was felt (▶ Fig. 1).



So, an orthopantomogram (OPG) was taken. OPG revealed three well-defined radiolucent lesions surrounded by radiopaque border present on right and left side of body of mandible and also there was pathological migration of premolars present on left and right sides. The third lesion was present in left ramus of mandible. So further for three-dimensional evaluation of the lesion cone beam computed

tomography (CBCT) was taken with 10×5 field of view and three-dimensional assessment was done. CBCT revealed well-defined hypodense lesion on both sides of body of mandible with expansion of the lesion anteroposteriorly and buccally with perforation of the buccal cortical plate but there was no evidence of lingual cortical plate expansion. The lesion measured approximately $35.5 \text{ mm} \times 16.1 \text{ mm}$

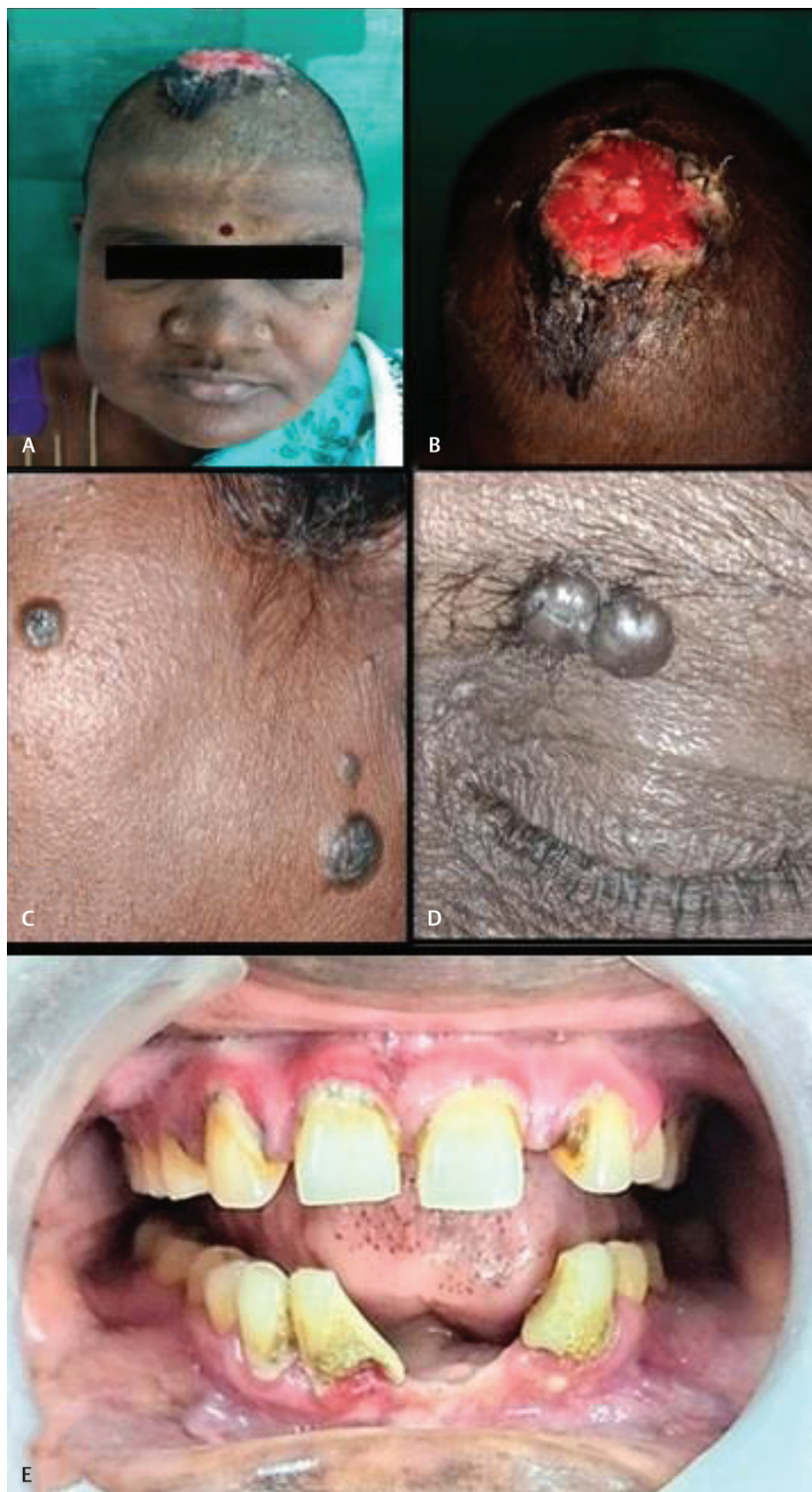

Fig. 1 (A) Extraoral view revealing facial asymmetry on right side; (B) ulcer on scalp covered with granulation tissue; (C, D) multiple compound nevus on face; (E) Intraoral examination showing obliteration of buccal vestibule from 44 to 47 and 35 to 37 with normal mucosal color and periodontally compromised teeth.

and 39.5 mm × 17.7 mm on right and left sides, respectively. The lesion in the left ramus on coronal section measured about 32.0 mm × 14.3 mm in its maximum dimension with expansion and perforation of the cortical bone (►Fig. 2). So, by analyzing these radiographic image findings, the lesion was interpreted as odontogenic keratocyst (OKC). So, by considering the multiple cystic lesions on mandible an assumption of Gorlin–Goltz syndrome was made. Later, anteroposterior view (AP) of skull was suggested which showed ectopic calcification of falx cerebri (►Fig. 2). Chest X-ray was taken but there was no evidence for bifid or splayed ribs.

So, considering the clinical findings, such as histopathologically proven BCC, with radiographic image analysis of multiple cystic lesions of jaws and calcification of falx cerebri, the case was diagnosed as Gorlin–Goltz syndrome and further investigations and treatment procedures were planned for the patient. Routine blood investigations were taken, which were all within the normal levels. The patient was prescribed antibiotics to treat infections in the oral cavity and the patient was planned for surgical enucleation of cysts. Under general anesthesia the cystic lesions on both sides of the mandible were enucleated along with the extraction of teeth in the involved region and

send for histopathological evaluation. The histopathological examination in × 10 and × 40 magnification view revealed cyst wall lined by corrugated parakeratotic stratified squamous epithelium with basal cuboidal to columnar palisading epithelium cells, underlying fibrocollagenous stroma shows collection of inflammatory cell infiltrate composed of plasma cells, lymphocytes and local lymphoid aggregate formation, and projection of satellite cysts (►Fig. 3). The BCC on scalp was treated with flap surgery by the surgical oncology department. Now the patient is under regular follow-up. Postoperative OPG picture (►Fig. 3), and pre- and posttreated clinical pictures (►Fig. 3) after 1-year follow-up are shown.

Discussion

Gorlin–Goltz syndrome is a rare genetic disorder. It is believed to be caused by mutation in the human patched gene (*PTCH1* gene) that is present in the long arm of chromosome 9q22.3-q31.² Sahu et al reported two cases from mother and daughter.³ The characteristic features of this syndrome was first recorded by Jarish and White in 1894, but later in the 1960s Gorlin and Goltz described them as a triad of disorders including multiple BCC, numerous keratocysts in the jaws, and skeletal abnormalities,

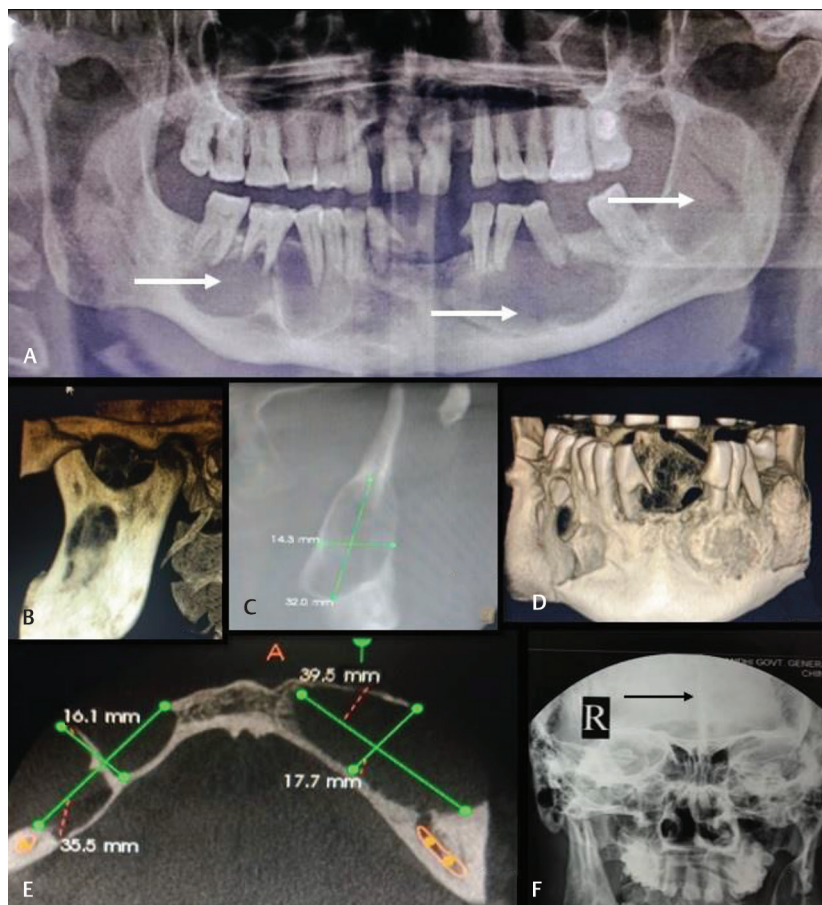


Fig. 2 (A) OPG shows well-defined three radiolucent lesions surrounded by radiopaque border present on right and left body and left ramus of the mandible. There is pathological migration of lower premolars on either side of mandible. No evidence of any root resorption. (B) Three-dimensional (3D) image reconstruction of left ramus. (C) Coronal section of left ramus showing expansion of lingual cortical plate with lesion measuring approximately (32.2 mm × 14 mm) in its maximum dimension. (D) 3D image reconstruction of mandible. (E) Axial section measuring approximately (35.5 mm × 16.1 mm and 39.5 mm × 17.7 mm) at its greatest dimension on right and left side respectively. (F) AP view skull showing ectopic calcification of falx cerebri. AP, anteroposterior; OPG, orthopantomogram.

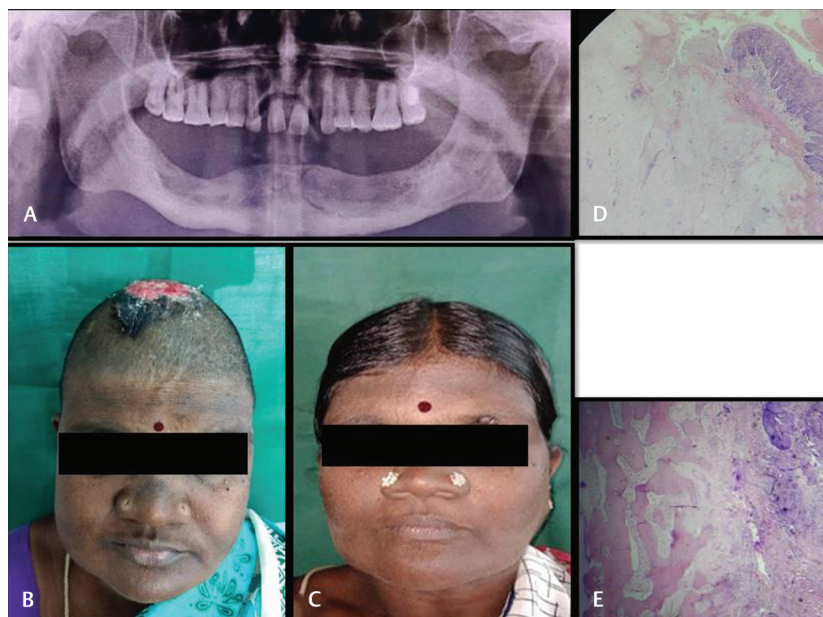

Fig. 3 (A) Postoperative OPG taken after 1-year follow-up. (B, C) Preoperative and postoperative clinical pictures. Photomicrograph of H&E stained histological section under $\times 10$ and $\times 40$ magnification shows (D) corrugated parakeratotic stratified squamous epithelium with basal cuboidal to columnar palisading epithelium cells, (E) underlying fibrocollagenous stroma with collection of inflammatory cell infiltrate. H&E, hematoxylin and eosin; OPG, orthopantomogram.

which gave upsurge to the Gorlin–Goltz syndrome.⁴ Clinical indicators of the syndrome are grouped into the following five categories. Cutaneous anomalies include basal cell nevus, other benign dermal cysts and tumors, palmar pitting, palmar and plantar keratosis, and dermal calcinosis. Dental and osseous deformities include multiple OKCs, mild mandibular prognathism, frontal and temporoparietal bossing, kyphoscoliosis or other vertebral defects, and bifurcated ribs. Ophthalmic differences include hypertelorism, wide nasal bridge, dystopia canthorum, congenital blindness, and internal strabismus. Neurological variances include mental retardation, dural calcification, bridging of sella, agenesis of corpus callosum, congenital hydrocephalus, and medulloblastoma. Sexual malfunctions include hypogonadism and ovarian tumor-like fibrosarcoma.⁵ Evans et al first ascertained the major and minor criteria for the diagnosis of the syndrome which were later revised by Kimonis et al in 2004. More than 100 minor criteria have been described. The presence of two major and one minor or one major and three minor criteria is essential to establish a diagnosis.⁶ The *major criteria* include the following:

- Multiple BCCs >2 , or one occurring under the age of 20 years.
- Histologically proven OKCs of the jaws.
- Palmar or plantar pits (three or more).
- Bilamellar calcifications of the falx cerebri.
- Bifid, fused, or markedly splayed ribs.
- First-degree relative with nevoid BCC (NBCC) syndrome.

Minor Criteria

- Macrocephaly (adjusted for height).
- Congenital malformation: cleft lip or cleft palate, frontal bossing, and coarse face moderate or severe hypertelorism.

- Other skeletal abnormalities: Sprengel deformity, marked pectus deformity, and marked syndactyly of the digits.
- Radiological abnormalities: bulging of sella turcica, vertebral anomalies, such as hemivertebrae, fusion or elongation of vertebral bodies, modeling defects of the hands and feet, or flame-shaped hands or feet.
- Ovarian fibroma.
- Medulloblastoma.

In this case, the diagnosis was made by two major criteria, such as multiple cystic lesions of jaws and calcification of falx cerebri and three minor criteria which include multiple compound nevus with histopathologically proven BCC and slight mandible prognathism.

Skin lesions, such as cutaneous nevus, underline the early onset with BCCs up to 90% of patients by the age of 40 years. The presence of the lesion may vary from brownish colored nevi to very aggressive BCC usually in sun-exposed areas.⁷ So, it is crucial to make an initial diagnosis as these patients may be shown increased risk of transformation into malignant neoplasms. They are also sensitive to ionizing radiation, mainly ultraviolet radiation. Confirmation of the diagnosis is done by DNA analysis which remains as the gold standard. Therefore, genetic counseling is anticipated for all patients and their family members with this condition.⁸ The diagnostic protocol for evaluation of the patient with suspected NBCC syndrome comprises complete patient history and clinical, dermatological, radiological, dental, cardiac, and gynecological examinations.⁹ Multiple OKCs alone may be confirmatory of the syndrome. Treatment usually involves removal of tumors by surgical excision, laser ablation, photodynamic therapy, or topical chemotherapy, but radiotherapy remains a contraindication.¹⁰

Prognosis

Most of the anomalies in Gorlin–Goltz syndrome are minor and usually not life-threatening. The prognosis depends on the behavior of skin tumors. In a few cases, aggressive BCCs have triggered the death of the patient due to tumor invasion of the brain or other vital structures. The jaw cysts are treated by enucleation but in many patients, secondary cysts will continue to develop. Varying degrees of jaw deformity may result from operations of multiple cysts and infection from the cysts is also not uncommon.¹¹

Conclusion

Gorlin–Goltz syndrome is an infrequent but important entity. So, once a diagnosis is confirmed, it is essential for the patient to be appropriately managed and observed periodically. Prenatal, counseling can be given for suspected couples who are at risk. Since this syndrome is less familiar, the lack of awareness can lead to delayed diagnosis.

Conflict of Interest

None declared.

Acknowledgments

The authors sincerely acknowledge the following institutes for their support:

1. Department of Surgical Oncology, Rajiv Gandhi Government General Hospital, Chennai.
2. Institute of General Pathology Rajiv Gandhi Government General Hospital, Chennai.
3. Department of Oral and Maxillofacial Surgery, Tamil Nadu Government Dental College and Hospital, Chennai.

References

- 1 Thomas N, Vinod SV, George A, Varghese A. Gorlin–Goltz syndrome: An often missed diagnosis. *Ann Maxillofac Surg* 2016;6(1):120–124
- 2 Guruprasad Y, Prabhu PR. Gorlin–Goltz syndrome with situs oppositus. *Natl J Maxillofac Surg* 2010;1(1):58–62
- 3 Sahu S, Sahoo S, Banerjee R, Ghosh S. An enigma of Gorlin–Goltz syndrome: Two cases reported in mother and daughter. *J Oral Maxillofac Pathol* 2019;23(Suppl 1) :115–121
- 4 Kiwilsza M, Sporniak-Tutak K. Gorlin–Goltz syndrome—a medical condition requiring a multidisciplinary approach. *Med Sci Monit* 2012;18(9):RA145–RA153
- 5 Jawa DS, Sircar K, Somani R, Grover N, Jaidka S, Singh S. Gorlin–Goltz syndrome. *J Oral Maxillofac Pathol* 2009;13(2):89–92
- 6 Joshi PS, Deshmukh V, Golgire S. Gorlin–Goltz syndrome. *Dent Res J (Isfahan)* 2012;9(1):100–106
- 7 Witmanowski H, Szychta P, Błochowiak K, Jundził A, Czajkowski R. Basal cell nevus syndrome (Gorlin–Goltz syndrome): genetic predisposition, clinical picture and treatment. *Postepy Dermatol Alergol* 2017;34(4):381–387
- 8 Sebastian J, Nikhilraj, Shakunthala GK, Roshin CN. Diagnostic approach to recurrent multiple odontogenic Cyst–Gorlin–Goltz syndrome. *J Indian Acad Oral Med Radiol* 2019;31(1):84–87
- 9 Bree AF, Shah MR; BCNS Colloquium Group. Consensus statement from the first international colloquium on basal cell nevus syndrome (BCNS). *Am J Med Genet A* 2011;155A(9):2091–2097
- 10 Kalogeropoulou C, Zampakis P, Kazantzi S, Kraniotis P, Mastronikolis NS. Gorlin–Goltz syndrome: incidental finding on routine ct scan following car accident. *Cases J* 2009;2:9087
- 11 Charles A. Waldron. Nevoid Basal Cell Carcinoma Syndrome. In: Brad W. Neville, Douglas D. Damm, Carl M. Allen, Jerry E. Bouquot – 1st ed. *Oral and Maxillofacial Pathology*. Philadelphia: WB Saunders; 1995:501–503