



# Management of Intussusceptions Secondary to Pathological Lead Points in Infants and Children

Rajendra K. Ghritlaharey<sup>1</sup>

<sup>1</sup>Department of Paediatric Surgery, Gandhi Medical College and Associated Kamla Nehru and Hamidia Hospitals, Bhopal, Madhya Pradesh, India

**Address for correspondence** Rajendra K. Ghritlaharey, MS, MCh, FAIS, MAMS, DLitt, Department of Paediatric Surgery, Gandhi Medical College and Associated Kamla Nehru and Hamidia Hospitals, Bhopal 462001, Madhya Pradesh, India (e-mail: drrajendrak1@rediffmail.com).

Ann Natl Acad Med Sci (India):2021;57:53–57

## Abstract

**Objectives** This study was undertaken to investigate and review the age, sex, clinical presentation, surgical procedures done, major postoperative complications, and the final outcome of infants and children operated for intussusceptions secondary to pathological lead points (PLPs).

**Materials and Methods** This is a single-institution, retrospective study and included infants and children below the age of 12 years who were operated for the secondary intussusceptions. This study was conducted at author's Department of Paediatric Surgery during the last 20 years; from January 1, 2000 to December 31, 2019.

**Results** During the study period, 200 infants and children were operated for the intussusceptions, and 23 (11.5%) of them were operated for the intussusceptions secondary to PLPs. This review comprised 18 (78.26%) boys and 5 (21.73%) girls, and consisted of infants ( $n = 9$ , 39.13%) and children of 1 to 5 years of age ( $n = 7$ , 30.43%) and 6 to 12 years of age ( $n = 7$ , 30.43%). The age at presentation ranged from 3 months to 10 years, with the mean age of  $41.47 \pm 40.06$  months. Clinically, all the children presented with features of acute intestinal obstruction. Ultrasonography (USG) examination of the abdomen revealed the diagnosis of intussusception in all of them but not able to document the PLPs as a cause for it. During the exploratory laparotomies, gangrenous bowel was detected in 15 (65.21%) cases. PLPs causing intussusceptions were Meckel's diverticulum ( $n = 17$ , 73.91%), begin ileal growth ( $n = 4$ , 17.39%), benign ileal polyp ( $n = 1$ , 4.34%), and caecal lymphoma ( $n = 1$ , 4.34%). Surgical procedures were executed in the following order of frequency: (1) resection of segment of ileum including PLP, and ileoileal anastomosis ( $n = 13$ , 56.52%); (2) resection of segment of ileum including PLP, caecum and part of ascending colon, and ileoascending anastomosis ( $n = 5$ , 21.73%); (3) Meckel's diverticulectomy ( $n = 3$ , 13.04%); and (4) resection of segment of ileum including PLP and terminal ileostomy ( $n = 2$ , 8.69%). This study documented two (8.69%) deaths in postoperative period.

**Conclusion** Meckel's diverticulum was the commonest pathology for the secondary intussusceptions in infants and children and documented most frequently during infancy. Half of the secondary intussusceptions occurred within 24 months of age. Bowel resection was required in more than 85% of the cases during the surgical procedures.

## Keywords

- ▶ children
- ▶ infants
- ▶ intestinal obstruction
- ▶ intussusception
- ▶ Meckel's diverticulum
- ▶ pathological lead points
- ▶ secondary intussusception

published online  
February 8, 2021

DOI <https://doi.org/10.1055/s-0040-1722536>  
ISSN 0379-038X.

© 2021. National Academy of Medical Sciences (India).

This is an open access article published by Thieme under the terms of the Creative Commons Attribution-NonDerivative-NonCommercial-License, permitting copying and reproduction so long as the original work is given appropriate credit. Contents may not be used for commercial purposes, or adapted, remixed, transformed or built upon. (<https://creativecommons.org/licenses/by-nc-nd/4.0/>).  
Thieme Medical and Scientific Publishers Pvt. Ltd. A-12, 2nd Floor, Sector 2, Noida-201301 UP, India

## Introduction

The word intussusception is derived from the Latin words “intus” (within) and “suscipere” (to receive). Intussusception is the invagination of one part of the intestine into another.<sup>1</sup> Intussusception remains a most frequent cause of acute bowel obstruction in infants and young children.<sup>1,2</sup> In developing countries, management of intussusception in children is associated with significantly higher morbidity and mortality.<sup>3-5</sup> Approximately 95% of the intussusceptions in children are idiopathic in nature, where there is no identifiable cause for it.<sup>1-4</sup> Secondary intussusceptions are caused by identifiable cause/pathological lead points (PLPs) and reported to occur in up to 20% of the cases, and more likely to occur in older children.<sup>1,2,4,6-8</sup> Present review consists of 23 infants and children below the age of 12 years who were operated for the intussusceptions secondary to PLPs.

## Materials and Methods

This is a single-institution, retrospective study and included infants and children under the age of 12 years and who were operated for the intussusceptions secondary to PLPs. This study was conducted at the author's Department of Paediatric Surgery during the last 20 years; from January 1, 2000 to December 31, 2019. Medical records of all the infants and children ( $n = 23$ ) were reviewed for their age, sex, clinical presentation, surgical procedures executed, postoperative major complications, and the final outcome.

## Results

During the study period, 23 infants and children below the age of 12 years were operated for intussusceptions secondary to PLPs. Demographic details of these 23 infants and children are provided in ►Table 1. The age at presentation ranged from 3 months to 10 years, with the mean age of  $41.47 \pm 40.06$  months. Clinically, all of them presented with the features of acute intestinal obstruction. Per-abdominal examination also supported the diagnosis of intestinal obstruction in all of them. Plain skiagram of the abdomen was ordered in all and was suggestive of intestinal obstruction. Ultrasonography (USG) examination of the abdomen revealed the diagnosis of intussusception in all of them but not documented the PLPs as a cause for it. During the exploratory laparotomy, due to the late presentation, gangrenous bowel was detected in 15 (65.2%) of the cases. PLPs causing intussusceptions in infants and children are provided in the ►Fig. 1. Surgical procedures executed for above-mentioned infants and children are detailed in the ►Fig. 2. Postoperatively, major complications were observed in three (13.04%), two of the infants documented anastomotic leak and another child developed septicemia. Two of the infants who had anastomotic leak needed re-exploration for the repair of the anastomotic leakage. Third child developed septicemia, and he was treated with antibiotics and other supportive measures. Follow-up period ranged from 3 months to 1 year. A child who had caecal

growth, his histopathology report was caecal lymphoma, and was referred to further management to medical oncologist, and he was lost to follow-up. This study documented two (8.69%) deaths following the surgical management of intussusceptions caused by PLPs in infants and children.

## Discussion

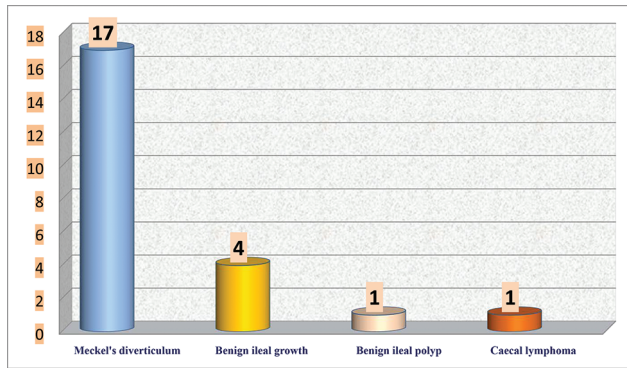
Intussusception is one of the most frequent causes of acute bowel obstruction in infants and young children, but it can also affect older children and adolescents.<sup>1-5,8,9</sup> Approximately 95% of the intussusceptions in infants and children are idiopathic in nature where there is no identifiable cause for it.<sup>1,2,4</sup> Secondary intussusception results when there is an identifiable cause for it, and reported to occur in 0.3 to 20% of the cases in infants and young children.<sup>1,2,4,6,10</sup> PLPs causing intussusceptions are more likely to be reported in older children.<sup>6,8</sup> Intussusception is also occurring in adults but as a rare clinical entity.<sup>11-13</sup> Contrary to the childhood intussusceptions, adult intussusceptions are mostly due to the secondary pathological conditions, and PLPs are reported to occur in up to 90% of the cases.<sup>11,13</sup>

Two hundred infants and children were operated for the intussusceptions during the study period, and the above-mentioned 23 (11.5%) infants and children were intussusceptions secondary to the PLPs. Thirteen (56.52%) of them were below the age of 2 years at the time of presentation, and nine (39.13%) were infants. Present study documented male preponderance with male-to-female ratio of 3.6:1. All the 23 infants and children with intussusceptions secondary to PLPs presented with the features of an acute intestinal obstruction, although two of them also had previous history of off and on abdominal pain for past 6 months. The classic triads (vomiting, abdominal pain, and passage of blood through rectum) and further the classic four symptoms (abdominal pain and vomiting) and signs (abdominal mass and rectal bleeding) were present in all of the intussusceptions secondary to PLPs patients. Abdominal examination of above-mentioned cases also documented features of intestinal obstruction. All of the infants and children with secondary intussusceptions were investigated with routine hematological investigations. Radiological investigations ordered were standing skiagram and USG examinations of the abdomen. Standing skiagram of the abdomen revealed multiple air fluid levels and was suggestive of intestinal obstruction in all of them. USG examination of the abdomen reported as dilated bowel loops, features of bowel obstruction, and intussusception as a cause for bowel obstruction in all the cases. It was possible to document the diagnosis of intussusceptions during abdominal sonography in all the cases, but PLPs were not documented in any of the above cases. USG examination of the abdomen is a well-established diagnostic tool for the diagnosis of intussusception in children.<sup>14,15</sup> It is also possible to detect and demonstrate the PLP shadows during abdominal sonography in many of the secondary intussusceptions in children.<sup>16</sup>

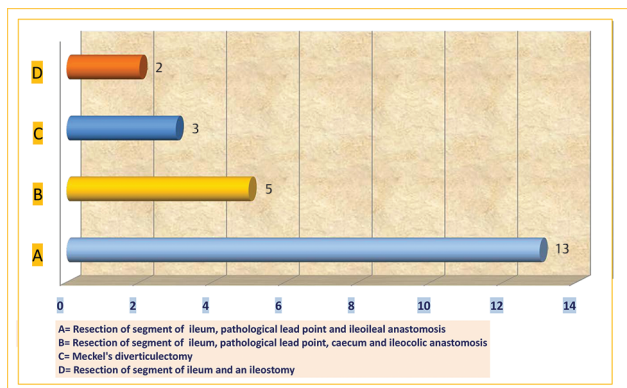
**Table 1** Demographics details of infants and children operated for the intussusceptions secondary to the pathological lead points (n = 23), from January 1, 2000 to December 31, 2019

Serial number	1	2	3	4	5	6	7	8	9	10	11	12	13	14	15	16	17	18	19	20	21	22	23
Month and year operated	February, 2000	August, 2003	May, 2004	August, 2005	May, 2006	December, 2008	May, 2010	April, 2012	November, 2013	February, 2014	April, 2014	May, 2014	July, 2014	August, 2014	March, 2015	June, 2015	October, 2015	May, 2016	December, 2016	April, 2017	September, 2017	October, 2017	March, 2019
Age (mo)	6	4	3	5	18	5	72	120	7	60	84	24	12	108	4	48	18	96	36	72	24	120	8
Sex (M/F)	M	M	M	M	M	M	M	M	F	M	F	M	F	M	M	M	M	M	M	F	F	M	M
Complaints (int. obstruction)	Yes	Yes	Yes	Yes	Yes	Yes	Yes	Yes	Yes	Yes	Yes	Yes	Yes	Yes	Yes	Yes	Yes	Yes	Yes	Yes	Yes	Yes	Yes
Abd. examination (int. obstruction)	Yes	Yes	Yes	Yes	Yes	Yes	Yes	Yes	Yes	Yes	Yes	Yes	Yes	Yes	Yes	Yes	Yes	Yes	Yes	Yes	Yes	Yes	Yes
X-ray abd. (int. obstruction)	Yes	Yes	Yes	Yes	Yes	Yes	Yes	Yes	Yes	Yes	Yes	Yes	Yes	Yes	Yes	Yes	Yes	Yes	Yes	Yes	Yes	Yes	Yes
USG diagnosis of intussusception	Yes	Yes	Yes	Yes	Yes	Yes	Yes	Yes	Yes	Yes	Yes	Yes	Yes	Yes	Yes	Yes	Yes	Yes	Yes	Yes	Yes	Yes	Yes
PLPs (USG)	No	No	No	No	No	No	No	No	No	No	No	No	No	No	No	No	No	No	No	No	No	No	No
Pre-op diagnosis of intussusception	Yes	Yes	Yes	Yes	Yes	Yes	Yes	Yes	Yes	Yes	Yes	Yes	Yes	Yes	Yes	Yes	Yes	Yes	Yes	Yes	Yes	Yes	Yes
Intussusception (anatomical type: ileocolic/ileoileal type)	Ileocolic	Ileocolic	Ileocolic	Ileocolic	Ileocolic	Ileocolic	Ileoileal	Ileocolic	Ileocolic	Ileocolic	Ileocolic	Ileocolic	Ileocolic	Ileocolic	Ileocolic	Ileocolic	Ileocolic	Ileocolic	Ileocolic	Ileocolic	Ileocolic	Ileocolic	Ileocolic
Gangrenous bowel (yes/no)	Yes	Yes	Yes	Yes	Yes	Yes	Yes	No	Yes	No	Yes	Yes	No	Yes	No	No	No	Yes	No	No	Yes	Yes	Yes
PLPs	MD	MD	MD	MD	MD	MD	MD	Ileal polyp	MD	MD	MD	MD	MD	MD	Ileal growth	Caecal growth	Ileal growth	MD	MD	Ileal growth	Ileal growth	MD	MD
Surgical procedures	-	-	-	-	-	-	-	-	-	-	-	-	-	-	-	-	-	-	-	-	-	-	-
Resection of segment of ileum, PLP and ileoileal anastomosis	Yes	Yes	Yes	Yes	Yes	-	Yes	Yes	Yes	-	Yes	Yes	-	Yes	-	-	-	-	-	-	-	-	-
Resection of segment of ileum, PLP, caecum and ileocolic anastomosis	-	-	-	-	-	Yes	-	-	-	-	-	-	-	-	Yes	Yes	Yes	-	-	Yes	-	-	-
Meckel's diverticulectomy	-	-	-	-	-	-	-	-	-	Yes	-	-	Yes	-	-	-	-	-	Yes	-	-	-	-
Resection of segment of ileum, PLP and ileostomy	-	-	-	-	-	-	-	-	-	-	-	-	-	-	-	-	-	-	-	-	-	Yes	Yes
Complications	Nil	Nil	Leak	Leak	Septic	Nil	Nil	Nil	Nil	Nil	Nil	Nil	Nil	Nil	Nil	Nil	Nil	Nil	Nil	Nil	Nil	Nil	Nil
Remarks	Well	Well	Well	Death	Death	Well	Well	Well	Well	Well	Well	Well	Well	Well	Well	Well	Well	Well	Well	Well	Well	Well	Well

Abbreviations: Abd., abdomen; F, female; Int., intestinal; MD, Meckel's diverticulum; M, male; PLPs, pathological lead points; Pre-op, preoperative; USG, ultrasonography.



**Fig. 1** Intussusceptions secondary to pathological lead point in infants and children ( $n = 23$ ).



**Fig. 2** Operative procedures executed for intussusceptions secondary to pathological lead point in infants and children ( $n = 23$ ).

In present report, Meckel's diverticulum was the commonest pathology and was observed in 17 (73.91%) cases, followed by benign ileal growth ( $n = 4$ , 17.39%), benign ileal polyp ( $n = 1$ , 4.34%), and caecal lymphoma ( $n = 1$ , 4.34%). In general, the pathologies/PLPs causing secondary intussusceptions in children are either intraluminal or intramural or extrinsic pathologies. Meckel's diverticulum is a leading cause for secondary intussusception and reported to occur in 20 to 50% of the cases.<sup>1,2,4,6,7,10,17</sup> Other pathologies causing secondary intussusception in children are ileal polyp, duplication of ileum, benign, Peutz-Jeghers syndrome, malignant tumors, and appendiceal stump.<sup>1,2,4,6,7,14,15</sup>

The initial management for the intussusception in children is hydrostatic/pneumatic reduction with added advantage of nonoperative nature with shorter hospital stay. Absolute contraindications for the institution of above nonoperative therapy are presence of bowel ischemia/gangrene, bowel perforation, and peritonitis. The success of pneumatic/hydrostatic reduction is directly related to the early diagnosis of intussusceptions and institution of above therapy.<sup>18-20</sup>

Surgical therapy is required for the cases that failed to nonoperative therapy, had bowel gangrene, bowel perforation and peritonitis, neonatal intussusception, and cases with a prior diagnosis of PLPs for intussusception.<sup>18,19</sup> Das et al retrospectively reviewed 1,588 intussusception cases from 19 Indian hospitals among children between 2

and 23 months of age, and they documented that nonoperative reduction was successfully done in 50.8% of the cases and surgical therapy was required in 41% of the cases.<sup>21</sup>

In general, intussusceptions secondary to PLPs require surgical therapy.<sup>4,6-8,14,22-24</sup> In present report, all the infants and children were subjected to exploratory laparotomy after adequate resuscitation. Gangrenous bowel was documented during exploratory in 15 (65.21%) of the cases. Bowel resection was required in more than four-fifths ( $n = 20$ , 86.95%) of the cases. Although Meckel's diverticulum was the pathology for the secondary intussusceptions in 17 of the cases, but the Meckel's diverticulectomy was possible only in three of the cases, due to the presence of bowel gangrene. Major complications were observed in three of the cases in postoperative period. Two of the infants developed anastomotic leak and required reexploration for the repair of the same, and another child developed septicemia.

There is steady decline in the mortality relating to the management of the intussusceptions in children. It was 59% during the year 1922, 27% in 1947, which is now declined to less than 1% in developed countries.<sup>2,25</sup> In developing countries, management of intussusceptions in children is still associated with significantly high morbidity and mortality. This morbidity and mortalities are directly related to the delayed diagnosis, presence of bowel gangrene, and the need for major bowel resections during the surgical therapy.<sup>3-5,25</sup> In a systematic review relating to the global epidemiology of intussusception in children under the age of 5 years revealed that in Africa, many of the children presented late, had advanced stage of illness, more number of children required surgical therapy, and also associated with higher mortality as compared to the other parts of the world.<sup>25</sup> Two (8.69%) deaths documented following the surgical management of intussusceptions secondary to PLPs in infants and children in present report. Deaths were contributed by delayed presentation, presence of bowel gangrene, requirement of bowel resection during surgical procedures, and postoperative complications as anastomotic leak required reexploration in one and septicemia in another children.

## Conclusion

Meckel's diverticulum was the commonest pathology for secondary intussusceptions in infants and children, and it was documented in approximately three-fourths of the cases. Among nine infants, included in this study, eight of them documented Meckel's diverticulum as pathology for secondary intussusceptions. This review documented male preponderance. Half of the cases of secondary intussusceptions occurred within 24 months of the age. During surgical procedures, bowel resection was required in 85% of the cases, and the requirement of the bowel resection was due to the presence of gangrenous bowel in 65% of the cases.

## Conflict of Interest

None declared.



## References

- 1 Columbani PM, Scholz S, Intussusception. In: Coran AG, Adzick NS, Krummel TM, Laberge, et al, eds. In: *Pediatric Surgery*. 7th ed. Philadelphia, PA: Elsevier Inc.; 2012:1093–1110
- 2 Takeuchi M, Osamura T, Yasunaga H, Horiguchi H, Hashimoto H, Matsuda S. Intussusception among Japanese children: an epidemiologic study using an administrative database. *BMC Pediatr* 2012;12:36
- 3 Ekenze SO, Mgbor SO. Childhood intussusception: the implications of delayed presentation. *Afr J Paediatr Surg* 2011;8(1):15–18
- 4 Pandey A, Singh S, Wakhlu A, Rawat J. Delayed presentation of intussusception in children—a surgical audit. *Ann Pediatr Surg* 2011;7:130–132
- 5 Carapinha C, Truter M, Bentley A, Welthagen A, Loveland J. Factors determining clinical outcomes in intussusception in the developing world: experience from Johannesburg, South Africa. *S Afr Med J* 2016;106(2):177–180
- 6 Banapour P, Sydorak RM, Shaul D. Surgical approach to intussusception in older children: influence of lead points. *J Pediatr Surg* 2015;50(4):647–650
- 7 Maazoun K, Mekki M, Sahnoun L, et al. [Intussusception owing to pathologic lead points in children: report of 27 cases] (in French). *Arch Pediatr* 2007;14(1):4–9
- 8 Wong CW, Jin S, Chen J, Tam PK, Wong KK. Predictors for bowel resection and the presence of a pathological lead point for operated childhood intussusception: A multi-center study. *J Pediatr Surg* 2016;51(12):1998–2000
- 9 Hwang S, Kim J, Jung JY, et al. The epidemiology of childhood intussusception in South Korea: an observational study. *PLoS One* 2019;14(12):e0219286
- 10 Fiegel H, Gfroerer S, Rolle U. Systematic review shows that pathological lead points are important and frequent in intussusception and are not limited to infants. *Acta Paediatr* 2016;105(11):1275–1279
- 11 Lianos G, Xeropotamos N, Bali C, Baltoggiannis G, Ignatiadou E. Adult bowel intussusception: presentation, location, etiology, diagnosis and treatment. *G Chir* 2013;34(9,10):280–283
- 12 Lindor RA, Bellolio MF, Sadosty AT, Earnest F IV, Cabrera D. Adult intussusception: presentation, management, and outcomes of 148 patients. *J Emerg Med* 2012;43(1):1–6
- 13 Gupta V, Doley RP, Subramanya Bharathy KG, et al. Adult intussusception in Northern India. *Int J Surg* 2011;9(4):297–301
- 14 Flaum V, Schneider A, Gomes Ferreira C, et al. Twenty years' experience for reduction of ileocolic intussusceptions by saline enema under sonography control. *J Pediatr Surg* 2016;51(1):179–182
- 15 Trigylidas TE, Hegenbarth MA, Patel L, Kennedy C, O'Rourke K, Kelly JC. Pediatric emergency medicine point-of-care ultrasound for the diagnosis of intussusception. *J Emerg Med* 2019;57(3):367–374
- 16 Zhang Y, Dong Q, Li SX, et al. Clinical and ultrasonographic features of secondary intussusception in children. *Eur Radiol* 2016;26(12):4329–4338
- 17 Snyder CL. Meckel's diverticulum. In: Coran AG, Adzick NS, Krummel TM, et al, eds. In: *Pediatric Surgery* 7th ed. Philadelphia, PA: Elsevier Inc.; 2012:1085–1092
- 18 Simon NM, Joseph J, Philip RR, Sukumaran TU, Philip R. Intussusception: Single center experience of 10 years. *Indian Pediatr* 2019;56(1):29–32
- 19 Fahiem-UI-Hassan M, Mufti GN, Bhat NA, et al. Management of intussusception in the era of ultrasound-guided hydrostatic reduction: a 3-year experience from a tertiary care center. *J Indian Assoc Pediatr Surg* 2020;25(2):71–75
- 20 Thanh Xuan N, Huu Son N, Huu Thien H. Treatment outcome of acute intussusception in children under two years of age: A prospective cohort study. *Cureus* 2020;12(4):e7729
- 21 Das MK, Arora NK, Gupta B, et al. Intussusception in children aged under two years in India: Retrospective surveillance at nineteen tertiary care hospitals. *Vaccine* 2020;38(43):6849–6857
- 22 Lin XK, Huang XZ, Bao XZ, Zheng N, Xia QZ, Chen CD. Clinical characteristics of Meckel diverticulum in children: a retrospective review of a 15-year single-center experience. *Medicine (Baltimore)* 2017;96(32):e7760
- 23 Lin XK, Xia QZ, Huang XZ, Han YJ, He GR, Zheng N. Clinical characteristics of intussusception secondary to pathologic lead points in children: a single-center experience with 65 cases. *Pediatr Surg Int* 2017;33(7):793–797
- 24 Zhao L, Feng S, Wu P, Lai XH, Lv C, Chen G. Clinical characteristics and surgical outcome in children with intussusceptions secondary to pathologic lead points: retrospective study in a single institution. *Pediatr Surg Int* 2019;35(7):807–811
- 25 Clark AD, Hasso-Agopsowicz M, Kraus MW, et al. Update on the global epidemiology of intussusception: a systematic review of incidence rates, age distributions and case-fatality ratios among children aged <5 years, before the introduction of rotavirus vaccination. *Int J Epidemiol* 2019;48(4):1316–1326