



Management of Mesenteric Cysts in Pediatric Population: Five-year Experience in Tertiary Care Center

Shyamendra Pratap Sharma¹ Sarita Chowdhary¹ Pranay Panigrahi¹ Shiv Prasad Sharma¹

¹Department of Pediatric Surgery, Institute of Medical Sciences, Banaras Hindu University, Varanasi, Uttar Pradesh, India

Address for correspondence Shyamendra Pratap Sharma, Mch, Department of Pediatric Surgery, Institute of Medical Sciences, Banaras Hindu University, Varanasi, Uttar Pradesh 221005, India (e-mail: shyambrd07@gmail.com).

Ann Natl Acad Med Sci (India):2021;57:41–44

Abstract

Introduction To study the clinical features, diagnosis and treatment of mesenteric cysts in pediatric age group (< 15 years).

Materials and Methods This was a retrospective analysis which included 35 children diagnosed and treated for mesenteric cysts in the pediatric surgery department from January 2014 to January 2019. Patient's data were retrieved from case sheets and analyzed. Patients with at least one year follow-up were included in the study.

Results Thirty-five patients were included in the study. Twenty-one (60%) were males and fourteen (40%) were females. Mean age of presentation and surgery was 24 months. Twenty-six (74.2%) patients were managed by bowel resection, while 9 (25.7%) were managed by simple cystectomy. The average size of the cyst was 15 cm (ranging from 5 to 25 cm). Content of cysts was mostly chylous (82.9% cases). No recurrence was found throughout the follow-up period (1–2 years).

Conclusion Mesenteric cyst should be considered as a differential diagnosis in pediatric patients with acute or subacute intestinal obstruction and with or without a palpable lump in the abdomen. Mesenteric cysts can be managed surgically with favorable outcomes.

Keywords

- ▶ mesenteric cyst
- ▶ intestinal obstruction
- ▶ chylolymphatic cyst

Introduction

Mesenteric cyst is a rare abdominal tumor. Incidence of this lesion in the pediatric age group has been reported as 1 in 20,000 admissions.¹ They lack characteristic clinical features and radiological signs and thus encounter great diagnostic difficulties. The cyst may present as nonspecific abdominal features, acute abdomen, or an incidental finding. Abdominal pain is the major presenting symptom. Abdominal mass was reported to be present in more than 50% of cases and 40% of cases were discovered incidentally.^{1,2} Mesenteric cysts have been reported from the duodenum to the rectum and most of them are located in ileal mesentery.^{3–6}

Objectives

To study the clinical features, diagnosis, complications, and treatment of mesenteric cysts in the pediatric age group (< 15 years).

Materials and Methods

This study represents a retrospective analysis of 35 children diagnosed and treated for mesenteric cysts in the pediatric surgery department from January 2014 to January 2019. Patient's data were retrieved from case sheets and analyzed. Patients with at least 1-year follow-up were included in the study. Ultrasonography and CT scan of abdomen were done for imaging purposes. Patients with at least 1-year follow-up were included in the study. Patients of age more than 15 years and lost to follow-up were excluded. Clinical, radiological, peroperative, and histopathological findings were analyzed.

Results

Out of 35 patients, 21 (60%) were boys and 14 (40%) were girls, with male to female ratio of 1.5:1. The mean age at presentation was 24 months affecting newborns to twelve years of age. Twenty-two (62.8%) patients presented with

published online
October 25, 2020

DOI <https://doi.org/10.1055/s-0040-1718611>
ISSN 0379-038X.

© 2020. National Academy of Medical Sciences (India).

This is an open access article published by Thieme under the terms of the Creative Commons Attribution-NonDerivative-NonCommercial-License, permitting copying and reproduction so long as the original work is given appropriate credit. Contents may not be used for commercial purposes, or adapted, remixed, transformed or built upon. (<https://creativecommons.org/licenses/by-nc-nd/4.0/>).

Thieme Medical and Scientific Publishers Pvt. Ltd. A-12, 2nd Floor, Sector 2, Noida-201301 UP, India

subacute intestinal obstruction, 9 (25.7%) patients with a palpable abdominal mass, and the rest (4–11.4%) were diagnosed intraoperatively when laparotomy was done for other acute abdominal conditions. Ultrasonography was done in 31 (88.5%) cases, while CT scan of abdomen was done in 23 (65.7%) patients (►Table 1). Most of the mesenteric cysts were ileal mesentery 27 (77.1%) (►Fig. 1), followed by five (14.3%) cases in jejunal mesentery, 2 omental cysts (►Fig. 2), and 1 colonic cyst (►Fig. 3). Twenty-six (74.2%) patients were managed by bowel resection, while 9 (25.7%) were managed by simple cystectomy. Twenty-one (60%) cases of cyst were multiloculated, while 14 (40%) cases were uninoculated. Mean size of cysts was 15 cm (range from 5 to 25 cm) in largest diameter. Content of cysts was mostly chylous (82.9% cases), serous in 2 cases, and mixed in 4 cases (►Table 2). Histopathology showed lining of the cyst wall varied from flattened endothelial layer to a cuboidal/columnar layer and no malignant transformations were seen. Three patients developed adhesive ileus within 3 months of follow-up in the postoperative period which were managed conservatively. Recurrence was not noted in follow-up of 2 years.

Discussion

Mesenteric cyst is defined as any cyst which arises from mesentery along the gastrointestinal tract from duodenum up to the rectum. The mesenteric cyst is a rare presentation and incidence is 1 in 105000 admissions to general hospital and 1 in 200000 admissions to pediatric hospital. One third of mesenteric cysts occur in children less than 10 years of age.³⁻⁷

Table 1 Patients details

Total patients = 35		Number	Percentages
Sex	Male	21	60%
	Female	14	40%
Age at presentation and surgery	< 1 year	5	14.2%
	1 to 5 years	18	51.1%
	> 5 years	12	34.2%
Clinical finding	Pain in abdomen only	22	62.8%
	Abdomen mass with pain	9	25.7%
	Incidentally	4	11.4%
Imaging of abdomen	Ultrasound	31	88.5%
	CT	23	65.7%
Presentation	Acute	12	34.3%
	Chronic	23	65.7%
Surgery	Emergency	12	34.3%
	Elective	23	65.7%
	Cyst excision	9	25.7%
	Cyst excision with resection and anastomosis of bowel	26	74.2%

The mesenteric cyst was first reported by anatomist Beneviem in 1507. In 1842, Von Rokitsansky was the first to describe a chylous mesenteric cyst. In 1880, French surgeon Tillaux carried out the first successful surgery. In 1883, the first marsupialization was done by Pean.⁸

The exact etiology of mesenteric cysts is not known. Various theories have been proposed such as failure of leaves of the mesentery to fuse, occult trauma, neoplasia, localized degeneration of lymph node, and obstruction and/or degeneration of exiting lymphatic channels.⁹

Published literatures describe the most common location of mesenteric cyst is small bowel mesentery. Ileal (60%) was

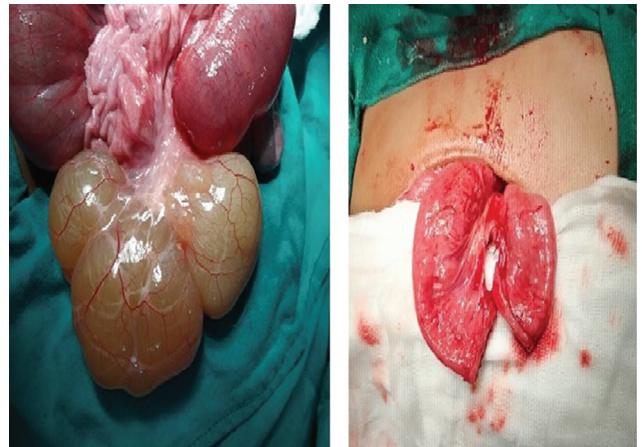


Fig. 1 A 5-year-old male patient with obstruction, ileal mesenteric cyst was found on laparotomy, resection of cyst with ileal segment and ileoileal anastomosis was done.

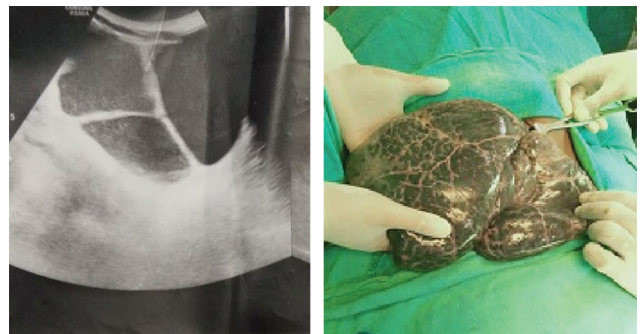


Fig. 2 Ultrasonography of a 3-year-old female with abdominal lump showing multiseptated large cyst, omental cyst was found on laparotomy, cystectomy with omentectomy was done.

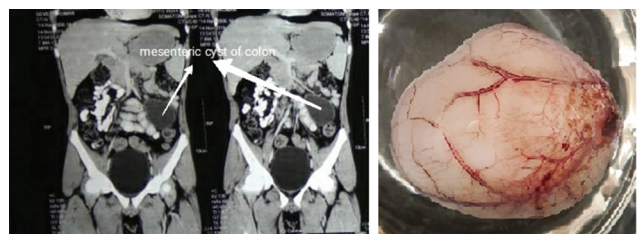


Fig. 3 CT scan abdomen of a 6-month-old male patient with left ileac fossa mass showing colonic cyst; laparotomy with excision of cyst was done.

Table 2 Cysts characteristics

Total patients = 35		Number	Percentage
Number	Single	9	25.7
	multiple	26	74.3
Site	Ileal	27	77.1
	Jejunal	5	14.3
	Mesocolon	1	2.8
	Omentum	2	5.7
Size	5 to 10 cm	21	60
	10 to 20 cm	10	28.5
	> 20 cm	4	11.4
Loculation	Single	14	40
	Multiple	21	60
Fluid content	Serous	2	5.7
	Chylous	29	82.8
	Serosanguinous	4	11.4
Lining of cyst wall	Flattened endothelial layer	8	22.9
	cuboidal / columnar layer	27	77.1

the most common type, followed by mesocolon (24%–most common sigmoid mesocolon), retroperitoneum (15%), and isolated omental cysts (< 1%).¹⁰ Mesenteric cyst can be single or multiple, unilocular or multilocular, and filled with content that can be serous (distal small bowel/colonic mesentery), chylous (proximal small bowel), hemorrhagic, or mixed.^{11,12} The lining of cyst can varied from flattened endothelial layer to a cuboidal or columnar layer.¹³ Similar findings were also observed in the study.

The classical presentation may varied from subacute intestinal obstruction combined with freely movable abdominal mass to acute abdomen.^{3,6} The most common mode of presentation in children was small bowel obstruction, which were associated with volvulus and intestinal perforation.^{3,6,11}

Ultrasonography (USG) of the abdomen have been preferred by many surgeons as investigation of choice.^{2,6} CT scan remains gold standard investigation as per may research papers for better anatomical orientation and identification of the adjacent organs.^{2,14} Although USG and/or CT scan of the abdomen is helpful in making the preoperative diagnosis of mesenteric cysts in a majority of the cases, it is not always possible and diagnosis is confirmed during surgical exploration many a times.^{3,15}

Management using surgical approach can involve simple drainage, resection either by laparotomy or minimal invasive approach. As a rule, drainage is not recommended because the cyst tends to reaccumulate, and marsupialization is not acceptable, because of the risk of infection and/or reoperation for persistently draining sinus.¹⁶ Full excision of the cyst with or without its mesenteric origin should be the aim of surgery, because recurrence is uncommon following total resection. Localized resection of the intestine with cyst does not significantly alter morbidity.¹⁷ Minimal access techniques have

been widely introduced in surgical practice. Laparoscopy provides visualization of the peritoneal cavity and retroperitoneal space and should prove to be the diagnostic procedure of choice in cases that remain unclear. Accurate anatomical, structural, and pathological assessment of the cyst can be made rapidly. In 1993, successful laparoscopic excision of mesenteric cysts was described by McKenzie.¹⁸ Laparoscopic surgery made it possible to remove cysts without complications in select cases; the postoperative period can be more comfortable. However, in cases where cysts cannot be completely excised, the requirement of the second operation and incomplete excision in retroperitoneal cases are disadvantages of laparoscopic surgery.¹⁸⁻²⁰

In our study, there were no deaths, and no patient complained of recurrence in follow-up. Prognosis following complete surgical excision of the mesenteric cyst is excellent, although recurrence has been reported and is more in the cases where the complete excision of the mesenteric cysts was not possible.¹⁻⁵

Conclusion

Mesenteric cysts should be considered as a differential diagnosis in pediatric patients with acute abdomen and with or without a palpable lump in the abdomen. Mesenteric cysts are managed surgically (excision of cyst along with adjacent bowel usually) with favorable outcomes either with open or laparoscopy; recurrence not reported with complete excision of the cyst.

Author Contributions

S.C.: planning and compiling data. S.P.S.: conducting study and writing paper, paper. P.P.: statistical analysis. S.P.S.: overall monitoring.

Ethical Approval

This study was approved by the Departmental Research Committee of the Department of Pediatric Surgery.

Conflict of Interest

None declared.

References

- 1 Chung MA, Brandt ML, St-Vil D, Yazbeck S. Mesenteric cysts in children. *J Pediatr Surg* 1991;26(11):1306–1308
- 2 Bezzola T, Bühler L, Chardot C, Morel P. [Surgical therapy of abdominal cystic lymphangioma in adults and children]. *J Chir (Paris)* 2008;145(3):238–243
- 3 Ricketts RR. Mesenteric and omental cysts. In: Arnold GC, Anthony C, Scott AN, et al. eds. *Pediatric Surgery*. 7th ed Elsevier Inc; 2012 1165–70
- 4 Takiff H, Calabria R, Yin L, Stabile BE. Mesenteric cysts and intra-abdominal cystic lymphangiomas. *Arch Surg* 1985; 120(11):1266–1269
- 5 Egozi EI, Ricketts RR. Mesenteric and omental cysts in children. *Am Surg* 1997;63(3):287–290
- 6 Bliss DP Jr, Coffin CM, Bower RJ, Stockmann PT, Ternberg JL. Mesenteric cysts in children. *Surgery* 1994;115(5):571–577
- 7 Pampal A, Yagmurlu A. Successful laparoscopic removal of mesenteric and omental cysts in toddlers: 3 cases with a literature review. *J Pediatr Surg* 2012;47(8):e5–e8

- 8 Mohanty SK, Bal RK, Maudar KK. Mesenteric cyst—an unusual presentation. *J Pediatr Surg* 1998;33(5):792–793
- 9 Farrell WJ, Grube P. Intra-abdominal cystic lymphangiomas. *Am J Surg* 1964;108:790–793
- 10 Caropreso PR. Mesenteric cysts: a review. *Arch Surg* 1974; 108(2):242–246
- 11 Rattan KN, Nair VJ, Pathak M, Kumar S. Pediatric chylolymphatic mesenteric cyst - a separate entity from cystic lymphangioma: a case series. *J Med Case Reports* 2009;3–111
- 12 Ulman I, Herek O, Ozok G, Avanoğlu A, Erdener A. Traumatic rupture of mesenteric cyst: a life-threatening complication of a rare lesion. *Eur J Pediatr Surg* 1995;5(4):238–239
- 13 Baker AH. Development mesenteric cysts. *Br J Surg* 1961; 48:534–540
- 14 Prakash A, Agrawal A, Gupta RK, Sanghvi B, Parelkar S. Early management of mesenteric cyst prevents catastrophes: a single centre analysis of 17 cases. *Afr J Paediatr Surg* 2010; 7(3):140–143
- 15 Nam SH, Kim DY, Kim SC, Kim IK. The surgical experience for retroperitoneal, mesenteric and omental cyst in children. *J Korean Surg Soc* 2012;83(2):102–106
- 16 Bill AH Jr, Sumner DS. A unified concept of lymphangioma and cystic hygroma. *Surg Gynecol Obstet* 1965;120:79–86
- 17 Mollitt DL, Ballantine TVN, Grosfeld JL. Mesenteric cysts in infancy and childhood. *Surg Gynecol Obstet* 1978; 147(2):182–184
- 18 Mackenzie DJ, Shapiro SJ, Gordon LA, Ress R. Laparoscopic excision of a mesenteric cyst. *J Laparoendosc Surg* 1993; 3(3):295–299
- 19 Vanek VW, Phillips AK. Retroperitoneal, mesenteric, and omental cysts. *Arch Surg* 1984;119(7):838–842
- 20 Sahin DA, Akbulut G, Saykol V, San O, Tokyol C, Dilek ON. Laparoscopic enucleation of mesenteric cyst: a case report. *Mt Sinai J Med* 2006;73(7):1019–1020