

Case Report

Osteocartilaginous choristoma of palatine tonsil: A rare entity

Ashima Batra¹, Shruti Dhingra², Mukta Pujani³, Aparna Khandelwal⁴, Kanika Singh⁵¹Department of Pathology, Positron Superspecialty & Cancer Hospital, Rohtak, Haryana, ²Department of ENT, Maulana Azad Medical College, New Delhi,³Department of Pathology, ESIC Medical College Faridabad, Paschim Vihar, New Delhi, ⁴Department of Pathology, SRL Diagnostic Lab, Chandigarh,⁵Department of Pathology, UCMS & GTB Hospital, New Delhi, India

ABSTRACT

Choristoma is the presence of normal tissue in an abnormal anatomical location. The presence of mature cartilage in the tonsil represents a choristoma as it is not a normal constituent of the tonsil and is a very rare entity. More than 70% of lingual choristomas occur in females; the tongue is the most common site, accounting for 80% of the cases. Osseous choristoma of the tongue is a rather rare entity, with less than 100 cases reported in the literature. We hereby report an osteocartilaginous choristoma of the palatine tonsil in a 42-year-old male patient who presented with a sore throat and difficulty in swallowing, for which he underwent tonsillectomy. Choristoma was an incidental discovery. Histopathology features were consistent with chronic tonsillitis along with incidental occurrence of hyaline cartilage and bone. As choristoma is a benign tumor that usually does not require any further treatment after simple excision, therefore no further treatment was given. The patient is currently under a 2-year follow-up and does not show any signs of recurrence. This case creates awareness about this rare entity among pathologists and clinicians so that overzealous and unnecessary treatment is avoided.

Keywords: Choristoma, ectopic tissue, heterotopic tissue, Palatine tonsil, oral cavity

INTRODUCTION

The neck region is known for various embryological anomalies on account of its complex development.¹ Choristoma is a developmental anomaly of the second pharyngeal arch,² which refers to the presence of histologically normal tissue or cells at an abnormal location. Cartilaginous choristomas occur in young females and are presented as firm to hard, painless nodules reported in the head and neck region.¹

Osteocartilaginous choristoma, consisting both osseous and cartilaginous tissues, is extremely rare in the oral cavity with only 10 cases documented in the English literature. In the oral cavity, the dorsum of the tongue is the usual site among women in their fifth decade of life. Etiology remains uncertain.³ Osteo-cartilaginous choristoma is very rare in tonsils.⁴⁻⁶

Osteocartilaginous choristoma is a well-defined swelling containing both osseous and cartilaginous tissues⁴. In the oral cavity, it is extremely rare with only nine cases reported in the English-language literature. At this site, these lesions especially involve the dorsum of the tongue in women from the 5th decade of life⁴. Etiology remains uncertain⁵ and

histopathology is characterized by a mass of osseous and cartilaginous tissues⁴. Management is based on complete surgical resection.⁶ Osteocartilaginous choristoma is a well-defined swelling containing both osseous and cartilaginous tissues⁴. In the oral cavity, it is extremely rare with only nine cases reported in the English-language literature. At this site, these lesions especially involve the dorsum of the tongue in women from the 5th decade of life⁴. Etiology remains uncertain⁵ and histopathology is characterized by a mass of osseous and cartilaginous tissues⁴. Management is based on complete surgical resection⁶ Osteocartilaginous choristoma is a well-defined swelling containing both osseous and cartilaginous tissues⁴. In the oral cavity, it is extremely rare with only nine cases reported in the English-language literature. At this site, these lesions especially involve the dorsum of the tongue in women from the 5th decade of life⁴. Etiology remains uncertain⁵ and histopathology is characterized by a mass of osseous and cartilaginous tissues⁴. Management is based on complete surgical resection⁶ Osteocartilaginous choristoma is a well-defined swelling containing both osseous and cartilaginous tissues⁴. In the oral cavity, it is extremely rare with only nine cases reported in the English-language

*Corresponding author: Dr. Mukta Pujani, MD Pathology, ESIC Medical College Faridabad, Haryana, India. drmuktapujani@gmail.com

Received: 28 November 2023 Accepted: 16 August 2024 Epub Ahead of Print: 22 November 2024 Published: *** DOI: 10.25259/ANAMS-2023-8-14-(1018)

This is an open-access article distributed under the terms of the Creative Commons Attribution-Non Commercial-Share Alike 4.0 License, which allows others to remix, transform, and build upon the work non-commercially, as long as the author is credited and the new creations are licensed under the identical terms. ©2024 Published by Scientific Scholar on behalf of Annals of the National Academy of Medical Sciences (India)

literature. At this site, these lesions especially involve the dorsum of the tongue in women from the 5th decade of life⁴. Etiology remains uncertain⁵ and histopathology is characterized by a mass of osseous and cartilaginous tissues⁴. Management is based on complete surgical resection⁶

CASE REPORT

A 42-year-old male presented to the clinic with recurrent episodes of sore throat for the past 2 years, along with difficulty in swallowing and snoring for the past 1 month. There was no history of ill-fitting dentures or any other dental problem. On examination, bilateral tonsils were enlarged with firm to hard areas on palpation. A provisional diagnosis of chronic tonsillitis with tonsilloliths was made. The dental examination was within normal limits. The rest of the head and neck regions did not reveal any abnormality. Bilateral tonsillectomy was performed, and the specimen was sent for histopathological examination. Written consent was obtained from the patient.

We received specimens of bilateral tonsils measuring $2 \times 1 \times 0.5$ cm and $2 \times 1.5 \times 0.5$ cm. Both cut surfaces were gray-white with few chalky white areas [Figure 1]. Histopathological examination revealed lymphoid hyperplasia, fibrosis areas, and mature hyaline cartilage islands [Figures 2a], occasional focus of mature bone formation [Figure 2b] and high power

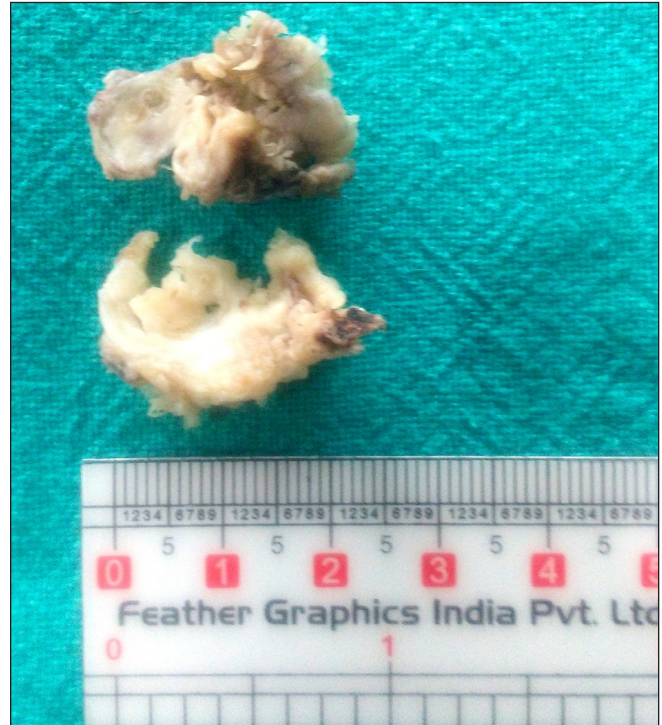

Figure 1: Gross photograph of cut surface of bilateral tonsils revealing gray white with few chalky white areas.

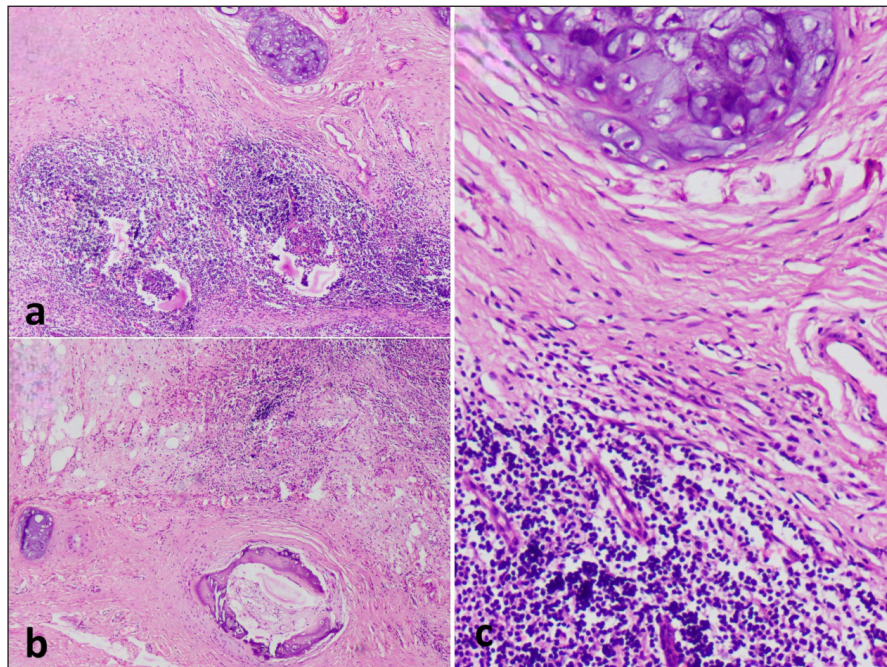


Figure 2: Microphotograph revealing (a) lymphoid hyperplasia, areas of fibrosis, and islands of mature hyaline cartilage (H&E; 40x); (b) occasional focus of mature bone formation (H&E; 40x) and (c) high power view of cartilage (H&E; 100x). H&E: Hematoxylin and eosin stain.

view of the cartilage [Figure 2c]. A diagnosis of osteocartilaginous choristoma of the tonsil was rendered. As choristoma is a benign tumor that usually does not require any further intervention or treatment after simple excision, and so no further treatment was given. The patient is currently under a 2-year follow-up, without any signs of recurrence.

DISCUSSION

Choristomas are benign lesions characterized by the presence of histologically normal tissue in abnormal locations due to developmental defects.¹ The age of diagnosis ranges from 10 to 80 years.⁷ Cartilaginous choristomas of the oral cavity are rare, and most of the choristomas are osseous with a predilection for the tongue followed by buccal mucosa and soft palate.^{4,8} Chondroid choristomas of the tongue mostly occur in females, while no sex predilection has been observed in palatine tonsil.⁷ Osseous choristoma of the tongue is a rather rare entity, with less than 100 cases reported in the literature. So far, very few cases of cartilaginous choristomas of the tonsils have been reported.

Usually, they are observed as incidental findings during histopathological examination of tonsillectomies performed

due to chronic tonsillitis. Erkilic *et al.* (2002) reported an incidence of 3% on tonsillectomy specimens.⁹ Sulhyan *et al.* (2016) in their study on tonsillar lesions found the incidence to be 2.84%.¹⁰ The present case is similar to the case by Pandey *et al.*² (2012), where patient presented with recurrent episodes of chronic tonsillitis and was diagnosed as choristoma later.

Several hypotheses have been proposed to explain the pathogenesis of choristoma. Haemel *et al.* (2008) concluded that it arises from mesenchymal progenitor cells having multilineage potential, which were able to differentiate into various mesenchymal cell types.¹¹ Lindholm *et al.* (1973) proposed that chemical or physical changes induced by chronic inflammatory processes could be responsible for the liberation of osteogenic substances, which stimulate heterotopic proliferation of cartilage.¹² The lateral part of the second pharyngeal arch leads to the development of tonsils. Partihiban *et al.* (2011) postulated that choristomas of the tonsil arise from embryological anomaly of the second pharyngeal arch, which leads to the occurrence of abnormal mesenchymal tissue in the tonsil.¹³

Table 1 depicts the spectrum of choristoma cases of the oral cavity over the last decade.

Table 1: Spectrum of choristoma cases of oral cavity over the last decade.

Authors	No. of cases	Age	Gender	Site	Type
Goncalo <i>et al.</i> ¹⁴ (2024)	1	72	F	Tongue	Cartilaginous
Ali <i>et al.</i> ¹⁵ (2024)	1	30	M	Nasopharynx	Cartilaginous
Shamloo <i>et al.</i> ¹⁶ (2023)	1	51	F	Palate	Osseous
Pol <i>et al.</i> ¹⁷ (2022)	2	30 52	F M	Soft palate Gingiva	Osseous Osseous
Amaral <i>et al.</i> ¹⁸ (2022)	1	38		Tongue	Osteocartilaginous
Arimoto <i>et al.</i> ¹⁹ (2021)	1	11	F	Tongue	Osseous
Gautam <i>et al.</i> ²⁰ (2021)	1	38	F	Tonsil	Cartilaginous
Bairwa <i>et al.</i> ⁶ (2018)	1	11	M	Tonsil	Osteocartilaginous
Camara <i>et al.</i> ³ (2017)	1	59	F	Tongue	Osteocartilaginous
Yoshimura <i>et al.</i> ²¹ (2018)	1	7	M	tongue	Osseous
Qin <i>et al.</i> ²² (2014)	1	8	M	Tongue	Osteocartilaginous
Meram <i>et al.</i> ²³ (2017)	1	3 months	F	Skull	Osteocartilaginous

Cartilage choristoma needs to be differentiated from metaplasia. Metaplasia is characterized histologically by diffuse calcific deposits and scattered chondrocytes in various stages of maturation single or as foci, whereas only mature tissue is present in choristoma.⁴

Excision remains the mainstay of treatment. In view of high recurrence rates in certain extraoral cases, excision should involve the removal of perichondrium as it has the potential to develop new cartilage, if left behind.⁷

CONCLUSION

Choristomas although rare entity, are usually discovered incidentally and are of academic interest only. They may be confused with true neoplasms if large in size or tonsilloliths in case of osseous or chondro-osseous choristoma. Moreover, the pathologist must be aware of this entity to avoid misdiagnosis of a benign incidental finding as some neoplasm.

Authors' contributions

M.P, A.K: Idea and design; A.B, K.S: Data acquisition; S.D, A.K: Analysis; S.D, K.S: Interpretation of findings; A.B: Preparation of manuscript; M.P: Critical revision.

Ethical approval

Institutional Review Board approval is not required.

Declaration of patient consent

The authors certify that they have obtained all appropriate patient consent.

Financial support and sponsorship

Nil.

Conflicts of interest

There are no conflicts of interest.

Use of artificial intelligence (AI)-assisted technology for manuscript preparation

The authors confirm that there was no use of AI-assisted technology for assisting in the writing of the manuscript, and no images were manipulated using AI.

REFERENCES

- Bedir R, Erdivanli ÖC, Erdivanli B, Sehitoglu İ, Dursun E. Cartilaginous choristoma of the tonsil: Three case reports. *Iran J Otorhinolaryngol* 2015;27:325–8.
- Pandey H, Thakur S, Gupta MK, Patiri K. Cartilaginous choristoma of palatine tonsil. *JCR* 2012;2:9–11.
- Câmara PR, dos Santos JF, Monteiro MCLJ, Menezes RER, Gouvêa AF, Fontes KBFC *et al.* Osteocartilaginous choristoma of the tongue: A case report and review of the literature. *J Oral Diag* 2017;2:e20170009.
- Shoba K, Harikumar, Srinivasan K, Raj KD. Osteo-cartilaginous choristoma of tonsil. *J Evol Med Dent Sci* 2014;3:8916–7.
- Ravindra S, Mannem C, Rangaswamy R, Agrawal A. Osteocartilaginous choristoma of tonsil: A report of two cases. *Arch Med Health Sci* 2019;7:78–80.
- Bairwa S, Sethi B, Singh P, Sangwaiya A, Kalhan S, Dutta S. Osteocartilaginous choristoma of palatine tonsil: A rare hidden entity. *Iran J Pathol* 2018;13:471–3.
- Sharma S, Makaju R, Shrestha B. Cartilaginous choristoma in tonsil: A rare entity. *ACCLM* 2015;1:49–50.
- Kannar V, Prabhakar K, Shalini S. Cartilaginous choristoma of tonsil: A hidden clinical entity. *J Oral Maxillofac Pathol* 2013;17:292–3.
- Erkiliç S, Aydin A, Koçer NE. Histological features in routine tonsillectomy specimens: The presence and the proportion of mesenchymal tissues and seromucinous glands. *J Laryngol Otol* 2002;116:911–3.
- Sulhyan KR, Deshmukh BD, Wattamwar RP. Histopathological spectrum of lesions of tonsil- A 2 year experience from tertiary care hospital of Maharashtra, India. *Int J Med Res Rev* 2016;4:2164–9.
- Haemel A, Gnepp DR, Carlsten J, Robinson-Bostom L. Heterotopic salivary gland tissue in the neck. *J Am Acad Dermatol* 2008;58:251–6.
- Lindholm TS, Hackman R, Lindholm RV. Histodynamics of experimental heterotopic osteogenesis by transitional epithelium. *Acta Chir Scand* 1973;139:617–23.
- Parthiban R, Sangeeta M, Santosh KV, Sridevi NS, Nandish C. Choristoma of the palatine tonsil. A case report. *Anatomica Karnataka* 2011;5:50–2.
- Gonçalo RIC, Medeiros HCM, dos Santos JLM, Sousa JT, Campos CM, Queiroz LMG. Oral A report of an unusual case of cartilaginous choristoma of the tongue and review. *Surgery* 2024;17:147–51.
- Ali MA, Hantzakos A. Cartilaginous choristoma of the oral cavity: A rare presentation in the nasopharynx. *Authorea* 2024.
- Shamloo N, Modanloo K, Khaleghi A. Osseous choristoma: Report of a case on the palate and a literature review. *Clin Case Rep* 2023;11:e8355.
- Pol VJ, Patil PR, Pol JN. Osseous choristoma: Report of two cases in oral cavity. *Indian J Pathol Oncol* 2022;9:279–81.
- Amaral de Freitas AM, Moreno Tarifa M, Tavares Abrahão AC, Mozardo Duarte G, Matsud Assunção T, Pirana S, *et al.* Choristoma of the dorsum of the tongue: A case report. *International Archives of Otorhinolaryngology*. 2022;26:40.
- Arimoto S, Shigeoka M, Akashi M. Tongue osseous choristoma in an 11-year-old female: A case report and literature review focusing on pediatric cases. *Case Rep Dent* 2021;2021:8021362.
- Gautam N, Makaju R, Basnet D, Lama B, Maharjan PB. Cartilaginous choristoma of tonsil: A hidden clinical entity. *Kathmandu Univ Med J (KUMJ)* 2021;19:528–30.
- Yoshimura H, Ohba S, Imamura Y, Sano K. Osseous choristoma of the tongue: A case report with dermoscopic study. *Mol Clin Oncol* 2018;8:242–5.
- Qin D, Tang Y, Ren D, Shen T, Li C, Geng N, *et al.* [Tongue osteocartilaginous choristoma: A case report]. *Hua Xi Kou Qiang Yi Xue Za Zhi* 2014;32:96–8.
- Meram E, Karabağlı H, Glastonbury C, Tihan T, Karabağlı P. Benign malformation lesion of the skull: Hamartoma with ectopic elements or choristoma? *Turk Patoloji Derg* 2017;33:262–7.

How to cite this article: Batra A, Dhingra S, Pujani M, Khandelwal A, Singh K. Osteocartilaginous choristoma of palatine tonsil: A rare entity. *Ann Natl Acad Med Sci (India)*. doi: 10.25259/ANAMS-2023-8-14-(1018)